Techniques in Knee Surgery 4(2):79–88, 2005
© 2005 Lippincott Williams & Wilkins, Philadelphia

TECHNIQUE

Lateral Unicompartmental Knee Arthroplasty

Amir A. Jamali, MD
Department of Orthopaedic Surgery
University of California Davis
Sacramento, California, U.S.A.

Richard D. Scott, MD
Department of Orthopaedic Surgery
Harvard Medical School
Arthroplasty Services
Brigham and Women's Hospital
New England Baptist Hospital
Boston, Massachusetts, U.S.A.

ABSTRACT

Arthritis of the lateral side of the knee makes up approximately one-eigth of cases of unicompartmental tibiofemoral arthritis. Surgical options for this disorder include unicompartmental knee replacement, fresh osteochondral grafting, osteotomies, and total knee replacement. Lateral unicompartmental knee replacements have achieved reliable improvements in pain and function and a high implant survival. The outcome of this procedure is largely dependent on appropriate patient selection and surgical technique. Lateral unicompartmental knee replacements are particularly at risk for failure due to patellofemoral degeneration as well as medial tibiofemoral arthritis. Both of these complications can be controlled by proper implant positioning and the avoidance of coronal alignment overcorrection.
Keywords: arthritis, knee, unicompartmental, arthroplasty, lateral

HISTORICAL PERSPECTIVE

Osteoarthritis of the knee affects approximately 1 in 10 members of the elderly population in the United States.[1] The radiographic prevalence is estimated to be even higher. Most cases of unicompartmental osteoarthritis involve the medial compartment.[2] The higher incidence of unicompartmental arthritis on the medial side has been attributed to variations in angular geometry of the lower extremity,[3] increased load bearing of the meniscus on the lateral side,[4] and differences in tibiofemoral kinematics between the compartments.[5]

Isolated lateral compartment osteoarthritis is relatively uncommon, accounting for 12.5% of all unicompartmental knee arthroplasties (UKA) performed in Sweden over an 8-year period.[2] The risk factors, clinical manifestations, and surgical treatment options for isolated lateral compartment are different from those of medial gonarthrosis. In this report, we aim to discuss the etiology, clinical presentation, and radiographic findings of lateral unicompartmental knee arthrosis with special emphasis on this condition with unicompartmental knee replacement.

INDICATIONS AND CONTRAINDICATIONS

Lateral unicompartmental arthritis, as an isolated entity, occurs relatively uncommonly. The relatively lower load on the lateral compartment is the most obvious reason for this low prevalence. In full extension, the pressure distribution ratio of medial to lateral knee compartments is nearly 2:1.[6] Normally, the weight-bearing or mechanical axis of the lower extremity during stance travels through the medial compartment.[3,7] Additionally, clinically, many patients seem to tolerate major structural damage and deformity better on the lateral side compared with the same degree of involvement on the medial side. Finally, lateral gonarthrosis occurs commonly with inflammatory arthritides and chondrocalcinosis, which are both relative contraindications to UKA. Lateral arthritis predominates in women with a long-standing tendency toward genu valgum.[8] In these individuals, the mechanical axis passes

Address correspondence and reprint requests to Amir A. Jamali, MD, Department of Orthopaedic Surgery, University of California Davis, Sacramento, CA 95817, U.S.A. E-mail: amir.jamali@ucdmc.ucdavis.edu

through the lateral side of the knee as a result of the coronal deformity. However, these patients often concurrently experience abnormal patellofemoral kinematics and patellar subluxation. Patellar subluxation is a major risk factor for the secondary degeneration of the patellofemoral joint, which often occurs in conjunction with lateral arthritis. In short, a number of factors are responsible for the relative paucity of patients with isolated lateral compartment arthritis. However, when such patients are encountered, lateral unicompartmental knee replacement with the appropriate selection criteria is a proven and reliable treatment option (Fig. 1)

Traditionally, UKA has been recommended for less active patients with minimal deformity, intact ligaments, and relatively low body weight. Although a number of reports have suggested a lower survival of UKA in younger, more active patients, other reports have demonstrated good results even in this subgroup.[9–11] In particular, the material improvements in polyethylene, refinements in surgical technique and instrumentation, and a better understanding of risk factors such as coronal overcorrection have improved the results of this procedure. For lateral UKA, relative contraindications include previous infection, young age, flexion contracture of >10°, a tibiofemoral angle of >15° valgus, excessive weight, high level of activity, anterior cruciate ligament insufficiency, and arthritis of the opposite tibiofemoral compartment or patellofemoral joint.

Although the literature points to a higher failure rate in patients with elevated body weight, it is difficult to establish a specific weight limit. Flexion contractures signify a change in the articular geometry of the joint and are indicative of global joint degeneration. Severe valgus deformities are contraindications for UKA due to the extensive lateral soft tissue contractures, attenuation of the medial collateral ligament and anterior cruciate ligament, as well as bone loss on the proximal tibia. Anterior cruciate ligament insufficiency has been associated with a higher failure rate after UKA and is considered a relative contraindication to the procedure.[10]

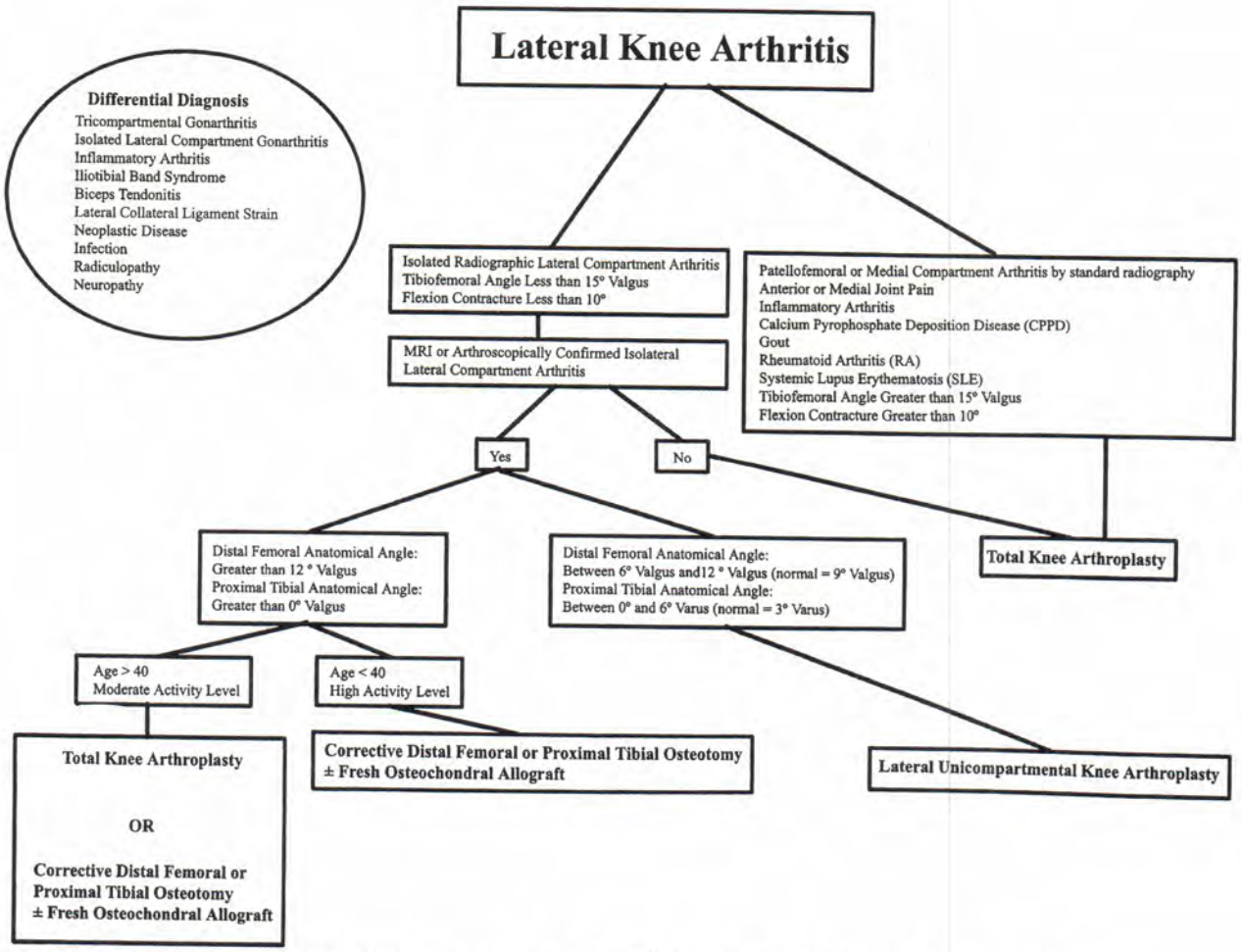

FIGURE 1. Treatment algorithm for lateral compartment arthritis after failure of nonsurgical management.

Alternative Surgical Options

Nonoperative treatment is the mainstay of treatment of lateral unicompartmental arthritis. The most effective modalities include activity modification, physical therapy, nonsteroidal anti-inflammatory medications, viscosupplementation, and chondroprotective agents such as chondroitin sulfate and glucosamine.

Surgical options for lateral knee arthritis include proximal tibial[12,13] and distal femoral[14–17] osteotomy. High tibial osteotomy is a potential option for patients with less severe valgus deformities such as a tibiofemoral angle of <12°. Comparison studies of high tibial osteotomies and unicompartmental knee replacements for medial arthritis have shown a higher complication rate,[18,19] more pain,[20] and an increased revision rate for the osteotomy group.[20] Furthermore, a number of reports have found that revision of a UKA to a total knee arthroplasty is less challenging than that of a high tibial osteotomy.[21,22]

Distal femoral varus osteotomy has achieved mixed results ranging from as high as 91%[23] to as low as 33%[15] satisfactory results. There has been a high complication rate including nonunion in more than one-fifth of patients.[14,15] The presence of severe articular cartilage disease has been associated with a less favorable outcome.[15] A number of recent reports have demonstrated marked improvements in pain and function in patients with failed high tibial osteotomy and distal femoral osteotomy procedures treated with total knee arthroplasty. However, these results are generally less favorable than those of primary total knee arthroplasty.[24,25] In summary, osteotomy is a valuable option in the treatment of isolated lateral knee arthritis when there is a significant deformity and in the absence of severe articular cartilage disease. These procedures are associated with a high complication rate, a significantly more difficult revision to total knee arthroplasty, and a less predictable outcome than after primary arthroplasty.

■ PREOPERATIVE PLANNING

A discussion of lateral UKA must first address the anatomic differences between the two tibiofemoral compartments. Since the majority of unicompartmental procedures are performed on the medial side, the surgeon must be aware of the variations in surgical approach, anatomic landmarks, pathologic changes, and kinematics of each compartment.

The femoral condyles are asymmetric, whereas the lateral condyle has an increasing radius of curvature posteriorly.[26] The long axis of the lateral femoral condyle is slightly longer and closer to the sagittal plane than that of the medial femoral condyle. The lateral condyle is slightly wider that the medial condyle at the center of intercondylar notch (Fig. 2).

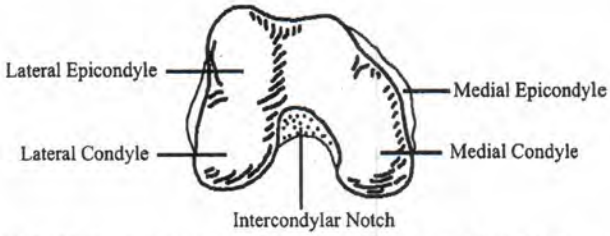

FIGURE 2. Diagrammatic representation of distal femoral condylar anatomy. (Adapted from Insall J, Scott N. *Surgery of the Knee.* New York: Churchill Livingstone; 2001).

The lateral tibial plateau tends to protrude 3–4 mm laterally compared with the lateral femoral condyle. This has implications when lining up the femoral and tibial components for their medial–lateral congruency. This can lead to a tendency to place the tibial component out toward the tibial cortex (not medial enough) such that the femoral component no longer articulates with the center of the tibial component. Additionally, the wear pattern in lateral osteoarthritis is posterior on both the femur and the tibia, whereas in medial arthritis, it is located anteriorly and peripherally.

The objective of UKA is to remove the isolated degenerated lateral compartment articular surfaces and to restore the knee to neutral anatomic alignment (tibiofemoral anatomic angle approximately 5–6° valgus). The pitfalls of the procedure relate to the over- or undercorrection of the coronal deformity, the placement of the tibial component with excessive posterior slope, and the excessively proud placement of the femoral component with impingement on the native patella.

Long-standing anteroposterior radiographs of both lower extremities and a lateral knee radiograph on a 14 × 17–in cassette are obtained. Calibration markers are used to determine the exact radiographic magnification. The principles of unicompartmental knee replacement are analogous to those of total knee arthroplasty. The major difference is that the adjustment of implant thickness affects only one compartment. For example, in the lateral compartment, use of a thicker polyethylene insert places the anatomic tibiofemoral axis into a varus alignment. The alignment of the distal femoral and proximal tibial articular surfaces is measured relative to the anatomic axes and is used to determine the distal femoral angle and proximal tibial angle. If there is a valgus deformity, the surgeon must determine whether it is a result of a tibial deformity, a femoral deformity, or intra-articular collapse in the setting of normal bony anatomy. If the deformity is extensive and is predominantly in the femur or tibia, UKA is less predictable than a corrective osteotomy or total knee arthroplasty.

The next step is the determination of the distal femoral resection. We prefer to establish the femoral component

perpendicular to the mechanical axis of the femur. The surgeon can determine the difference between the mechanical and anatomic axes of the femur. This angle represents the correction required on the cutting block to establish the distal femoral cut perpendicular to the mechanical axis. The amount of bone resected from the femur is measured based on the thickness of the femoral implant to restore the lateral femoral joint line (Fig. 3).

The tibial resection should be as small as possible and equivalent to the thinnest tibial implant available. This is particularly important on the lateral side owing to the relatively smaller anteroposterior dimension of the tibial plateau and the conical configuration of the tibia. An excessively generous resection can lead to implant overhang, an excessively thick polyethylene insert, and a more complex revision should total knee replacement become necessary. The determination of the native tibial slope is critical to avoid an excessively sloped tibial component. With this information, the tibial resection can be assessed intraoperatively. For example, in a knee with increased native posterior slope, the tibial resection should be thicker anteriorly.

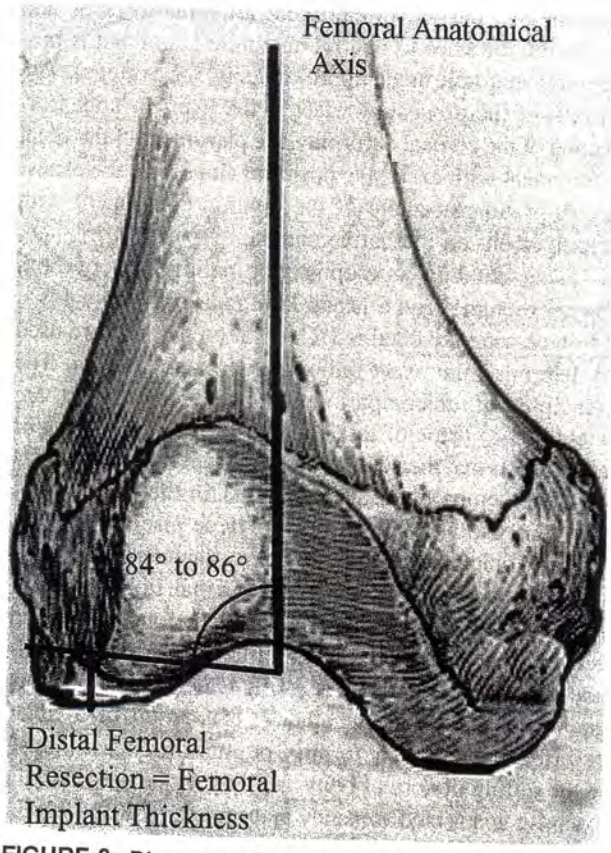

FIGURE 3. Diagrammatic representation of the distal lateral femoral bone cut. (Adapted from Tria AJ Jr, Klein KS. *An Illustrated Guide to the Knee.* New York: Churchill Livingstone; 1992).

Implant sizing is the final component of the preoperative planning. Each implant manufacturer provides radiographic overlays of the various implants available. This is most critical in knees at the extremes of available sizes.

■ TECHNIQUE

Lateral UKA can be performed through either a lateral parapatellar incision or a standard medial parapatellar arthrotomy. The advantage of a lateral incision is the ability to perform the procedure through a smaller incision with less soft tissue dissection. On the other hand, if the procedure is abandoned in favor of a total knee arthroplasty, a medial parapatellar incision for total knee replacement is more familiar for most surgeons than a lateral approach. If a medial incision is selected, the dissection is extended laterally, anterior to the coronary ligament to protect the medial meniscus. The patella is everted, and the knee is flexed. A portion of the Hoffa fat pad is removed from the anterior tibia to expose it for the tibial resection. An incision is made in the midcoronal plane of the lateral plateau just outside the lateral meniscus for placement of a bent Hohman retractor. For the lateral approach, the skin incision is approximately 3 in in length and extends from the superior pole of the patella to the level of the Gerdy tubercle. The deep dissection is through the lateral patellar retinaculum, anterior to the iliotibial band. The iliotibial band is released from its insertion on the Gerdy tubercle, leaving a 1-cm cuff for direct repair at the end of the procedure. Shorter incisions have been associated with less disruption of the quadriceps and earlier functional return.[27] Prior to performing any cuts, the medial and patellofemoral compartments are assessed for arthritic involvement. A minimal amount of chondromalacia is usually tolerated. The lateral meniscus is excised.

The distal femoral resection can be guided by intramedullary or extramedullary alignment. Intramedullary guides are accurate, but they have the disadvantage of increased invasiveness and risk of fat embolization. Regardless of the technique selected, the goal is to remove an amount of bone equivalent to the thickness of the femoral component and to restore the femoral joint line. The preferred angle of resection is approximately 5° valgus. The degree to which one can deviate from this angle depends on the congruence of the articulation in the coronal plane. For example, a round-on-round articulation is the most forgiving in this situation. In contrast, a flat-on-flat articulation demands complete accuracy in the coronal alignment to avoid any edge loading. Most implants are a variation of round on flat with the amount of forgiveness and the amount of contact area dependent on the difference of the radii of curvature of the implant components.

The extramedullary distal femoral resection is performed based on the previously performed tibial resection

(Fig. 4). The guide has a rectangular spacer block attached to it, which is of equivalent thickness to the selected tibial component. The guide is inserted with the knee flexed to the same degree as the previously resected tibial slope. Hyperextension of the knee should be avoided as doing so will lead to hyperextension of the femoral component. Slight flexion is beneficial as it facilitates increased metal-on-plastic contact in maximal knee flexion. The guide is pinned to the femur with two fixation pins, and the distal femoral resection is performed though a cutting slot in the guide. An adaptor block can be slid onto the pins to adjust the amount of resection proximally or distally, depending on the need to increase or decrease the extension gap.

Currently, many systems employ an intramedullary alignment guide on the femur (Fig. 5). The femoral canal is opened with a drill just anterior to the origin of the posterior cruciate ligament on the femur. If the arthroplasty is for posttraumatic arthritis after lateral plateau fracture, the cartilage of the distal femoral condyle is usually intact and must be removed with a scalpel. Otherwise, the distal resection will be inadequate to allow the leading edge of the femoral component to be recessed. In such cases, it is also prudent to err initially on underresecting the tibia to avoid facing a large extension gap. The distal femoral cut is then performed using a cutting jig with a small oscillating saw or reciprocating saw at the appropriate angle to the anatomic femoral axis (Fig. 6). The thickness of the fragment is measured with a caliper and is added to the saw blade thickness to determine the true resection and to avoid inadvertent alteration of the lateral joint line. An intramedullary patellar retractor is then inserted into the femoral intramedullary canal and is helpful in the final preparation of the femur and of the tibia (Fig. 7). Based on the cut distal femur, a second cutting block is applied to the distal femur with a foot plate that rests on the posterior femoral condyle. The sizing and rotation of the femoral component are determined at this point. In general, it is preferable to undersize the anteroposterior dimension of the femoral component to prevent patellar impingement. The patella often tracks to the lateral side particularly in patients with valgus alignment and lateral arthritis. As a result, extreme care is required to place the anterior flange of the femoral component flush with the adjacent bone. Hernigou and Deschamps have demonstrated patellofemoral impingement as a very common complication after lateral UKA, associated with placement of the femoral component in an excessively anterior position[28] (Fig. 8).

In regard to femoral component rotation, as the lateral femoral condyle is more in line with the sagittal plane than the medial femoral condyle, the femoral implant is placed in a slightly different orientation from that of a medial unicompartmental replacement. This is usually not a major issue, particularly with implant designs with a rounded femoral component and a relatively flat tibial component. The femoral preparation is then finalized either with angular chamfer cuts or burring technique based on the implant system selected.

For the tibial preparation, an extramedullary alignment rod is used. The distal aspect of the rod is brought in line with the tibial crest and the midpoint of the ankle joint distally, in a manner identical to that used for standard total knee arthroplasty. The tibial resection is performed with a reciprocating saw. In some cases, an additional 2–3 mm of resection medial to the initial cut in the sagittal plane is required after the use of the guide to account for the draping of the patellar tendon over the medial aspect of the lateral compartment. The medial margin of the tibial cut should be in line with the medial edge of the lateral femoral condyle when visualized from the anterior view. A posterior slope of 3–5° is optimal.

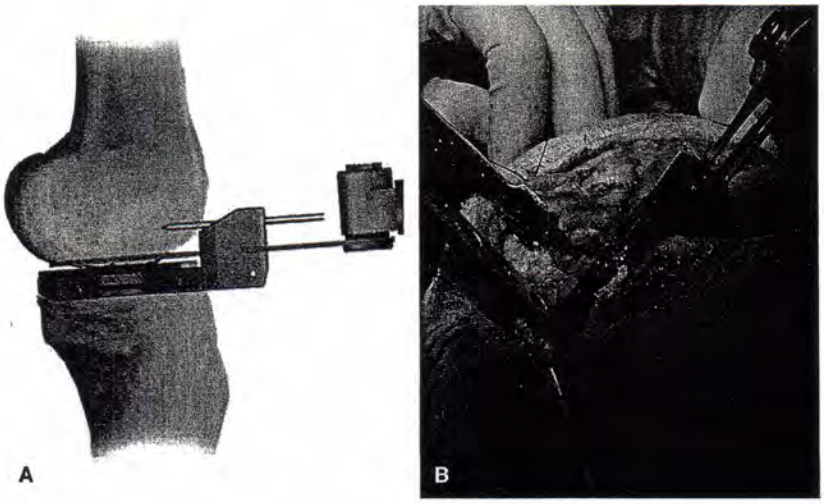

FIGURE 4. (A) Extramedullory technique for femoral resection (courtesy of Depuy, Warsaw, IN, USA). **(B)** Intraoperative photograph of distal femoral cut using the extramedullory technique.



FIGURE 5. Intramedullary femoral cutting guide (Zimmer, Warsaw, IN, USA).

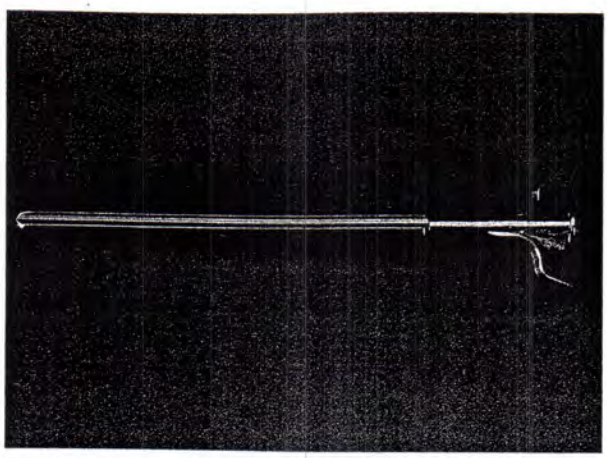

FIGURE 7. Intramedullary patellar retractor (Zimmer).

Hernigou and Deschamps have demonstrated a higher failure rate after UKA with a tibia slope >7°.[29]

At this point, trials implants are applied. With use of the above techniques, the extension and flexion gaps should be symmetric in the case of appropriate patient selection, femoral component sizing, and with restoration of the joint line. It is vital to check patellar tracking after placement of trials to avoid contact between the patella and the femoral component and to ensure that the femoral component is recessed flush with the anterior margin of the trochlea.

Next, the cancellous surfaces are cleaned with pulse lavage irrigation to remove any bone, blood, or fatty debris. It is preferable to test the real components in the knee prior to committing to the cementation process. Lugs or fins on the real components could make insertion more difficult than expected relative to lug-free trials in some implant systems. The cementation of the implants is performed initially on the tibial side. A surgical sponge is applied to the posterolateral edge of the joint with a curved Z retractor with its concavity aimed anteriorly. To avoid cement adhesion to metal implants, a small amount of adipose tissue is applied onto the tibial locking mechanism and onto the articular side of the femoral component

FIGURE 6. Selection of distal femoral resection angle on intramedullary femoral cutting guide (Zimmer).



FIGURE 8. Diagrammatic representation of patellar impingement from excessive anterior or proud placement of the femoral component. (Adapted with permission from Hernigou P, Deschamps G. Patellar impingement following unicompartmental arthroplasty. *J Bone Joint Surg Am.* 2002;84:1132–1137).

posteriorly. Cement is applied to the lug holes or slots and packed under pressure with essentially no cement applied to the plateau itself. The remaining cement is placed on the undersurface of the real tibial component. A very useful technique is to contact the tibial surface with the implant posteriorly and then to lay the implant down on the tibia more anteriorly. This minimizes cement extrusion posteriorly and allows extruded cement to come forward as the knee is extended. The Z retractor and sponge are then removed, bringing with them any extruded cement. Next, cement is applied to the prepared surface of the lateral femoral condyle with digital pressurization of the lug holes. A small aliquot is applied onto the implant posteriorly. If a modular tibial component is used, a trial insert is applied, and the knee is brought into extension. Axial compression is applied with the knee in full extension. Flexing and extending the knee during the polymerization process should be avoided as they may cause disruption of the prosthesis–cement or bone–cement interface. Once the cement is fully polymerized, residual cement can be removed from the back of the joint and the outer edges of the implants with an angled curette. A straight pituitary rongeur is passed along the tibial spine to confirm the absence of impingement between the implants and any retained bone or osteophyte. The final tibial level can be adjusted by varying the polyethylene insert thickness on modular systems, allowing final modification of the coronal correction. In general, both over- and undercorrection of coronal deformity should be avoided and a tibiofemoral angle of approximately 5–6° valgus should be achieved.

The capsule, resected synovium, and subcutaneous tissue are infiltrated with 0.25% bupivacaine for postoperative pain control. The use of suction drainage is optional. The closure is performed with absorbable interrupted sutures in the retinacular layer. The iliotibial band is directly repaired to the remaining tendon on the Gerdy tubercle. The subcutaneous layer is closed with a braided absorbable suture, and the skin is closed with a running subcuticular suture.

■ ILLUSTRATIVE CASES

A 72-year-old man presented with isolated lateral unicompartmental arthritis (Fig. 9A). He was treated with cemented lateral compartment UKA with an all-polyethylene tibial component (see Fig. 9B). Note the restoration of the tibiofemoral angle to 175° or 5° valgus.

A 43-year-old moderately active woman with a subtotal lateral meniscectomy 8 years prior to presentation presented with pain that localized to the lateral joint line (Fig. 10A). She had pseudolaxity to varus stress due to articular cartilage damage. She was initially evaluated arthroscopically and found to have pristine patellofemoral and medial knee compartments with exposed bone on the lateral femoral condyle and lateral tibial plateau and a small lateral meniscus remnant. She was treated with lateral unicompartmental knee replacement with a modular tibial component (see Fig. 10B). The final tibiofemoral angle was restored to 175° or 5° valgus.

■ RESULTS

Early reports on unicompartmental knee replacements noted better results on the lateral rather than medial side.[30–32] However, in these series, the follow-up was short, the

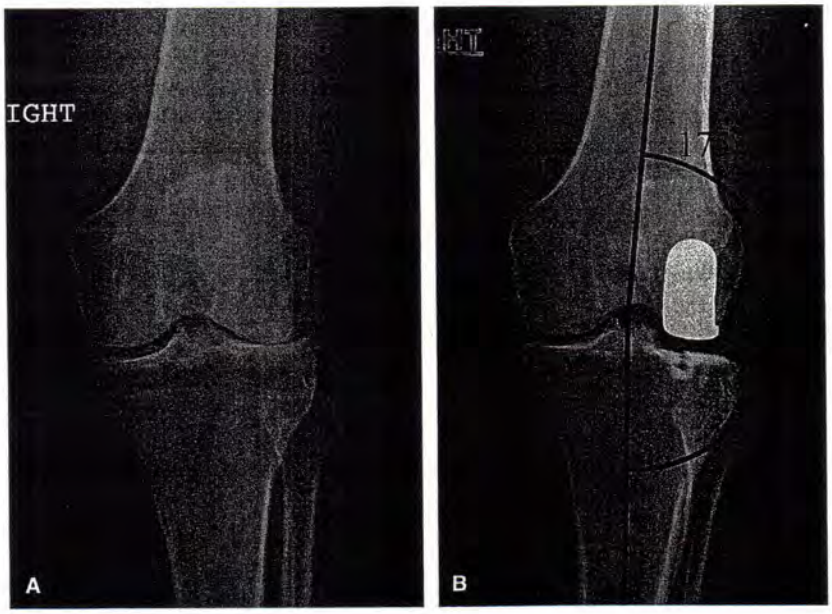

FIGURE 9. Preoperative **(A)** and postoperative **(B)** anteroposterior radiographs of a 72-year-old man with isolated lateral compartment osteoarthritis treated with lateral UKA.

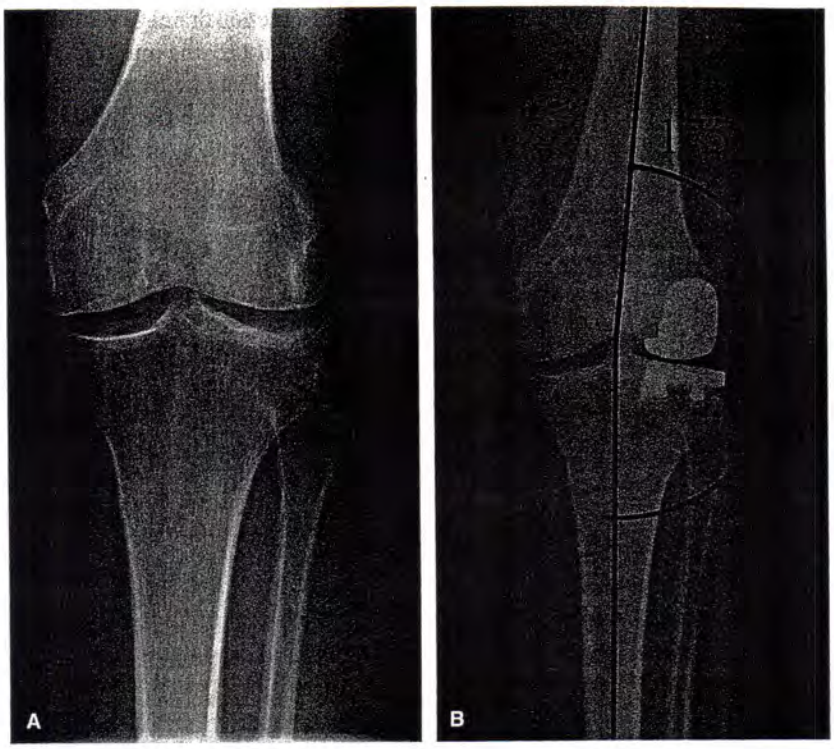

FIGURE 10. Preoperative **(A)** and postoperative **(B)** anteroposterior radiographs of a 43-year-old woman with postmeniscectomy isolated lateral compartment arthritis treated with a modular lateral UKA.

surgical techniques had not been refined, and the number of lateral UKA cases was small.

In spite of the large body of literature on UKA, relatively few publications have focused on lateral UKA specifically. Ohdera et al[33] retrospectively reviewed 18 cases of lateral UKA. At a mean follow-up of 8 years, five joints showed some progression of arthritis in the medial compartment. As a group, 16 of the 18 knees had a good or excellent Hospital for Special Surgery knee score at latest follow-up. As the mean patient weight in the series was only 58 kg, the results of this study may not be generalized to patients with increased body weight.

The Oxford UKA (Biomet, Warsaw, IN, U.S.A.) is a meniscal bearing prosthesis with a high degree of congruity between the femoral component and the articular surface of the polyethylene bearing. On the tibial side, the prosthesis has a flat, polished tibial plate upon which the bearing moves in both rotation and translation. The bearing is maintained in position by the soft tissue tension of the collateral ligaments. The advantage of the prosthesis is the low wear rate, attributed to the implant's congruent surfaces. In one series, this procedure was performed on the lateral side in 53 knees, of which 11 required further surgery (21%).[34] The results of the Oxford UKA on the medial side from the same institution were markedly better with a 98% survival at 10 years.[35] More than half of the reoperations for the Oxford lateral UKA were for dislocation of the bearing. The authors hypothesized that differences in soft tissue tension between the medial and lateral sides accounted for the relatively higher dislocation rate on the lateral side. Based on these results, it is critical to protect these structures when performing the lateral Oxford UKA.

Ashraf et al recently reported on 88 lateral UKA procedures at an average follow-up of 9 years. This series represents the longest period of follow-up of such a cohort in the literature. The St. Georg Sled (Waldemar Link, Hamburg, Germany) prosthesis was used in all cases. Fifteen knees required revision (17%). Nine cases had progression of arthritis, six had loosening, four had a fracture of the femoral component, and four had more than one reason for revision. The clinical scores from this study were comparable with literature values for medial UKA. Survival analysis at 10 years revealed a slightly lower survival in the lateral UKA group compared with previous results on the medial side from the same center (83% versus 87%).[36,37]

■ COMPLICATIONS

Excluding design-related factors, the most common complications after lateral UKA are progression of arthritis (medial or patellofemoral) and aseptic loosening. Although limited chondromalacia of the unresurfaced tibiofemoral compartment[38] and patellofemoral compartment[35,36,39] have been well tolerated in the literature, this scenario may increase the risk of ultimate degeneration in these compartments and lead to earlier revision.

A major technical error in the performance of UKA is overcorrection of the deformity in the coronal plane. Overcorrection has been associated with an increased risk of contralateral tibiofemoral degeneration. In fact, many authors have recommended undercorrection. Recent studies have shown that both undercorrection and overcorrection can be associated with a higher failure rate.[40,41] Undercorrection is associated with the use of thin inserts, which often leads to a higher wear rate. Overcorrection is a common pitfall particularly on the lateral side due to the decreased compliance of the lateral soft tissues.

■ POSTOPERATIVE MANAGEMENT

The postoperative regimen includes early mobilization with physical therapy on the day of surgery with additional use of cryotherapy. Most patients remain overnight for observation and pain control. The risk of venous thrombosis is low with the early mobilization protocol; however, anticoagulation is recommended. Patients are seen in follow-up at 1–2 weeks, at which point the need for outpatient physical therapy is determined.

■ CONCLUSION

Lateral isolated unicompartmental knee arthritis is a relatively rare condition. Various treatment options are available. In cases where the articular cartilage is damaged and in the absence of a deformity, UKA provides the optimal treatment. It has advantages of proven long-term durability, ability to be implanted through a smaller, less traumatic incision, and easier revision to total knee arthroplasty relative to alternative surgical treatments such as osteotomy. Furthermore, UKA is associated with a higher patient satisfaction[42] and lower implant cost than total knee arthroplasty.[43]

Ongoing technical advancements for unicompartmental knee replacements are emerging with the use of computerized surgical navigation. This tool will allow more precise implant placement and the avoidance of intramedullary guides. Surgical navigation when combined with our understanding of failure modes, complications, and patient selection will likely lead to further improvements in the results of this procedure.

■ REFERENCES

1. Felson DT, Naimark A, Anderson J, et al. The prevalence of knee osteoarthritis in the elderly. The Framingham Osteoarthritis Study. *Arthritis Rheum.* 1987;30:914–918.
2. Knutson K, Lindstrand A, Lidgren L. Survival of knee arthroplasties. A nation-wide multicentre investigation of 8000 cases. *J Bone Joint Surg Br.* 1986;68:795–803.
3. Cooke D, Scudamore A, Li J, et al. Axial lower-limb alignment: Comparison of knee geometry in normal volunteers and osteoarthritis patients. *Osteoarthritis Cartilage.* 1997; 5:39–47.
4. Walker PS, Erkman MJ. The role of the menisci in force transmission across the knee. *Clin Orthop.* 1975;109: 184–192.
5. Weidow J, Pak J, Karrholm J. Different patterns of cartilage wear in medial and lateral gonarthrosis. *Acta Orthop Scand.* 2002;73:326—329.
6. Kdolsky RK, Al Arabid B, Fuchs M, et al. Measuring the pressure pattern of the joint surface in the uninjured knee. *Klin Wochenschr Wien.* 2004;116:196–200.
7. Cooke TD, Pichora D, Siu D, et al. Surgical implications of varus deformity of the knee with obliquity of joint surfaces. *J Bone Joint Surg Br.* 1989;71:560–565.
8. Sharma L, Song J, Felson DT, et al. The role of knee alignment in disease progression and functional decline in knee osteoarthritis. *JAMA.* 2001;286:188–195.
9. Engh GA, McAuley JP. Unicondylar arthroplasty: An option for high-demand patients with gonarthrosis. *Instr Course Lect.* 1999;48:143–148.
10. Goodfellow J, O'Connor J. The anterior cruciate ligament in knee arthroplasty. A risk-factor with unconstrained meniscal prostheses. *Clin Orthop.* 1992;276:245–252.
11. Pennington DW, Swienckowski JJ, Lutes WB, et al. Unicompartmental knee arthroplasty in patients sixty years of age or younger. *J Bone Joint Surg Am.* 2003;85:1968–1973.
12. Coventry MB. Proximal tibial varus osteotomy for osteoarthritis of the lateral compartment of the knee. *J Bone Joint Surg Am.* 1987;69:32–38.
13. Shoji H, Insall J. High tibial osteotomy for osteoarthritis of the knee with valgus deformity. *J Bone Joint Surg Am.* 1973;55:963–973.
14. Edgerton BC, Mariani EM, Morrey BF. Distal femoral varus osteotomy for painful genu valgum. A five-to-11-year follow-up study. *Clin Orthop.* 1993;288:263–269.
15. Mathews J, Cobb AG, Richardson S, et al. Distal femoral osteotomy for lateral compartment osteoarthritis of the knee. *Orthopedics.* 1998;21:437–440.
16. Aglietti P, Menchetti PP. Distal femoral varus osteotomy in the valgus osteoarthritic knee. *Am J Knee Surg.* 2000;13:89–95.
17. Cameron HU, Botsford DJ, Park YS. Prognostic factors in the outcome of supracondylar femoral osteotomy for lateral compartment osteoarthritis of the knee. *Can J Surg.* 1997; 40:114–118.
18. Broughton NS, Newman JH, Baily RA. Unicompartmental replacement and high tibial osteotomy for osteoarthritis of the knee. A comparative study after 5-10 years' follow-up. *J Bone Joint Surg Br.* 1986;68:447–452.
19. Stukenborg-Colsman C, Wirth CJ, Lazovic D, et al. High tibial osteotomy versus unicompartmental joint replacement in

unicompartmental knee joint osteoarthritis: 7-10-year follow-up prospective randomised study. *Knee*. 2001;8:187–194.

20. Weale AE, Newman JH. Unicompartmental arthroplasty and high tibial osteotomy for osteoarthrosis of the knee. A comparative study with a 12- to 17-year follow-up period. *Clin Orthop*. 1994;302:134–137.
21. Levine WN, Ozuna RM, Scott RD, et al. Conversion of failed modern unicompartmental arthroplasty to total knee arthroplasty. *J Arthroplasty*. 1996;11:797–801.
22. Chakrabarty G, Newman JH, Ackroyd CE. Revision of unicompartmental arthroplasty of the knee. Clinical and technical considerations. *J Arthroplasty*. 1998;13:191–196.
23. McDermott AG, Finklestein JA, Farine I, et al. Distal femoral varus osteotomy for valgus deformity of the knee. *J Bone Joint Surg Am*. 1988;70:110–116.
24. Parvizi J, Hanssen AD, Spangehl MJ. Total knee arthroplasty following proximal tibial osteotomy: Risk factors for failure. *J Bone Joint Surg Am*. 2004;86:474–479.
25. Nelson CL, Saleh KJ, Kassim RA, et al. Total knee arthroplasty after varus osteotomy of the distal part of the femur. *J Bone Joint Surg Am*. 2003;85:1062–1065.
26. Insall J, Scott N. *Surgery of the Knee*. New York: Churchill Livingstone; 2001.
27. Price AJ, Webb J, Topf H, et al. Rapid recovery after Oxford unicompartmental arthroplasty through a short incision. *J Arthroplasty*. 2001;16:970–976.
28. Hernigou P, Deschamps G. Patellar impingement following unicompartmental arthroplasty. *J Bone Joint Surg Am*. 2002; 84:1132–1137.
29. Hernigou P, Deschamps G. Posterior slope of the tibial implant and the outcome of unicompartmental knee arthroplasty. *J Bone Joint Surg Am*. 2004;86:506–511.
30. Insall J, Walker P. Unicondylar knee replacement. *Clin Orthop*. 1976;120:83–85.
31. Insall J, Aglietti P. A five to seven-year follow-up of unicondylar arthroplasty. *J Bone Joint Surg Am*. 1980;62:1329–1337.
32. Laskin RS. Unicompartmental tibiofemoral resurfacing arthroplasty. *J Bone Joint Surg Am*. 1978;60:182–185.
33. Ohdera T, Tokunaga J, Kobayashi A. Unicompartmental knee arthroplasty for lateral gonarthrosis: midterm results. *J Arthroplasty*. 2001;16:196–200.
34. Gunther T, Murray D, Miller R, et al. Lateral unicompartmental arthroplasty with Oxford meniscal knee. *Knee*. 1996; 3:33–39.
35. Murray DW, Goodfellow JW, O'Connor JJ. The Oxford medial unicompartmental arthroplasty: A ten-year survival study. *J Bone Joint Surg Br*. 1998;80:983–989.
36. Ansari S, Newman JH, Ackroyd CE. St. Georg sledge for medial compartment knee replacement. 461 arthroplasties followed for 4 (1–17) years. *Acta Orthop Scand*. 1997;68: 430–434.
37. Ashraf T, Newman JH, Evans RL, et al. Lateral unicompartmental knee replacement survivorship and clinical experience over 21 years. *J Bone Joint Surg Br*. 2002;84:1126–1130.
38. Corpe RS, Engh GA. A quantitative assessment of degenerative changes acceptable in the unoperated compartments of knees undergoing unicompartmental replacement. *Orthopedics*. 1990;13:319–323.
39. Kozinn SC, Scott R. Unicondylar knee arthroplasty. *J Bone Joint Surg Am*. 1989;71:145–150.
40. Ridgeway SR, McAuley JP, Ammeen DJ, et al. The effect of alignment of the knee on the outcome of unicompartmental knee replacement. *J Bone Joint Surg Br*. 2002;84: 351–355.
41. Hernigou P, Deschamps G. Alignment influences wear in the knee after medial unicompartmental arthroplasty. *Clin Orthop*. 2004;423:161–165.
42. Laurencin CT, Zelicof SB, Scott RD, et al. Unicompartmental versus total knee arthroplasty in the same patient. A comparative study. *Clin Orthop*. 1991;273:151–156.
43. Robertsson O, Borgquist L, Knutson K, et al. Use of unicompartmental instead of tricompartmental prostheses for unicompartmental arthrosis in the knee is a cost-effective alternative. 15,437 primary tricompartmental prostheses were compared with 10,624 primary medial or lateral unicompartmental prostheses. *Acta Orthop Scand*. 1999;70: 170–175.