

# Multilevel Measurement of Acetabular Version Using 3-D CT-generated Models

## Implications for Hip Preservation Surgery

Aimee C. Perreira BS, John C. Hunter MD,  
Thaddeus Laird MD, Amir A. Jamali MD

Received: 11 December 2009 / Accepted: 30 August 2010 / Published online: 25 September 2010  
© The Author(s) 2010. This article is published with open access at Springerlink.com

### Abstract

**Background** Numerous structural deformities of the acetabulum are associated with hip osteoarthritis (OA). Acetabular retroversion has been implicated in the development of femoroacetabular impingement. However, it is unknown if retroversion occurs from isolated excessive bone in the superior acetabulum or a torsional phenomenon of the entire pelvic segment.

**Questions/purposes** A method was developed to measure acetabular version (AV) using 3-D models thus eliminating positional factors. This method was used to determine if acetabular retroversion is an isolated entity or an effect involving the entire pelvic segment containing the acetabulum.

**Method** Fifty pelvic CT scans were selected from a large database. Measurements were performed for abduction, ischial spine position, and AV at multiple levels. The relationships between anteversion at multiple levels and between midacetabular anteversion and ischial spine position were analyzed.

**Results** The mean upper and midlevel acetabular anteversion values were  $14.4^\circ \pm 10.5^\circ$  and  $21.3^\circ \pm 5.8^\circ$ , respectively. The mean abduction was  $39.7^\circ \pm 4.3^\circ$ . The prevalence of acetabular retroversion was 7%. Females had

greater anteversion than males at all levels. Correlations were found between Levels 1 and 4 version ( $r = 0.74$ ) and the ischial spine index and Level 4 version ( $r = 0.67$ ).

**Conclusions** These data suggest retroversion involves the acetabulum at all levels and includes the entire pelvic segment containing the acetabulum and the ischial spine.

**Clinical Relevance** These data are relevant for surgeons in providing targets for normal positioning of the acetabulum during periacetabular osteotomies and acetabular recontouring procedures.

### Introduction

OA of the hip is associated with numerous structural and morphologic abnormalities of the acetabulum, including hip dysplasia and acetabular retroversion [5, 8, 9, 16, 17, 23, 30, 35]. These disorders are characterized by abnormal acetabular bony coverage, depth, and orientation. These factors can alter load transmission across the hip, lead to instability, cause mechanical impingement, and ultimately damage the hip labrum and cartilage [7–9]. Some authors believe primary hip OA as an isolated entity is rare [10, 25, 31, 33] and more likely is attributable to abnormal anatomy that adversely affects the biomechanics of the hip [5]. Recognizing acetabular deformities and restoring normal anatomy may prevent the development of OA [5, 8, 17, 23, 30]. Numerous methods have been used to determine AV. These include direct manual measurements of cadaveric specimens, review of standard pelvic radiographs, measurement of 2-D axial CT cuts, and measurements from recently available 3-D models.

Retroversion has been defined as the tendency for the acetabulum to open posteriorly such that “the anterior edge of the mouth remains in a more lateral position than is

---

Each author certifies that he or she has no commercial associations (eg, consultancies, stock ownership, equity interest, patent/licensing arrangements, etc) that might pose a conflict of interest in connection with the submitted article.

Each author certifies that his or her institution approved the human protocol for this investigation, that all investigations were conducted in conformity with ethical principles of research.

---

A. C. Perreira, J. C. Hunter, T. Laird, A. A. Jamali (✉)  
Dept. of Orthopaedic Surgery, University of California Davis,  
4860 Y Street, #3800, Sacramento, CA 95817, USA  
e-mail: amir.jamali@ucdmc.ucdavis.edu

normal, and the posterior edge is more medial” [28]. This effect can be recognized on standard radiographs using the cross-over sign where the anterior rim of the acetabulum starts superiorly and laterally and crosses over the line of the posterior acetabulum more distally. The prevalence of acetabular retroversion diagnosed by the cross-over sign on plain radiography is reportedly 5% to 6% in the general population and as much as 20% in patients with OA of the hip [7, 9]. It has been associated with a posterior wall deficiency [9], excessive anterior coverage [7], or both. Giori and Trousdale sought to evaluate the radiographic appearance of the cross-over sign through the use of a wire along a 1-cm augmented rim or placed 1 cm medial to the normal acetabular rim on a model pelvis [9]. Their findings indicated that the cross-over sign most likely is associated with a posterior acetabular wall deficiency and a relatively normal anterior acetabular wall. Thus they stated that “posterior acetabular wall deficiency produces the cross-over sign... and torsional deformities do not” [9]. However, they did not take into account that the degrees of deformity may be much more subtle than a 1-cm overhang or deficiency. Furthermore, the degrees of deformity of the acetabulum can be variable in dimension from cranial to caudal. Ezo et al. determined the prevalence of acetabular retroversion in various pathologic conditions including dysplasia, osteonecrosis, OA, and Legg-Calvé-Perthes disease [7]. They also used the cross-over sign as a general test of retroversion but they determined the posterior wall sign to indicate “relatively less posterior coverage”. The posterior wall sign is positive when the line along the edge of the posterior wall is located medial to the center of the femoral head on the AP radiograph of the pelvis. They found a positive posterior wall sign in 19 of 21 hips with retroversion and a positive cross-over sign in their series. They surmised that a posterior wall sign indicates retroversion owing to torsion of the entire acetabulum. However, both of the preceding studies are limited by the lack of a systematic method of measurement of acetabular retroversion and depend on the presence or absence of these signs on standard radiographs. The studies do not fully address the key question of retroversion as being caused by excessive anterior bone, deficient posterior bone, or rather a torsional effect of the entire acetabulum. This issue was partially addressed in a recent radiographic study showing a correlation between the cross-over sign and the presence of an ischial spine projection into the pelvis on a standardized AP pelvic radiograph [15]. That study suggests a torsional effect of the entire pelvic segment containing the acetabulum and ischial spine in acetabular retroversion [15]. Thus the current tools available for analysis of retroversion include the cross-over sign, posterior wall sign, ischial spine projection into the pelvis [15], and measurements performed on 2-D axial CT sections.

When using 2-D axial CT sections, positional changes of the patient in the scanner, pelvic tilt, and variability from reader to reader can introduce inconsistencies in measurement for acetabular abduction and version [1, 14, 24, 29, 34, 37]. For example, if the pelvis was tilted slightly toward one side in the coronal plane, this would introduce distortion of the axial image, with the cut plane being angled proximally on the pelvis on one side and distally on the other side. An analogous distortion of the axial images also can occur with excessive native lumbar kyphosis or lordosis. To establish quantitative, multilevel measurements of AV and measure acetabular abduction and ischial spine position not prone to this source of error, we developed a method to quantify these values using computer-generated 3-D models that would be independent of all external factors.

We (1) established quantitative measurements of AV, acetabular abduction, and ischial spine position using 3-D CT generated models from an institutional database; (2) used the models to determine the prevalence of acetabular retroversion in this series of models, and (3) determined whether retroversion was isolated to the superior acetabulum or involved the entire acetabulum and/or the pelvic segment including the acetabulum and the ischial spine.

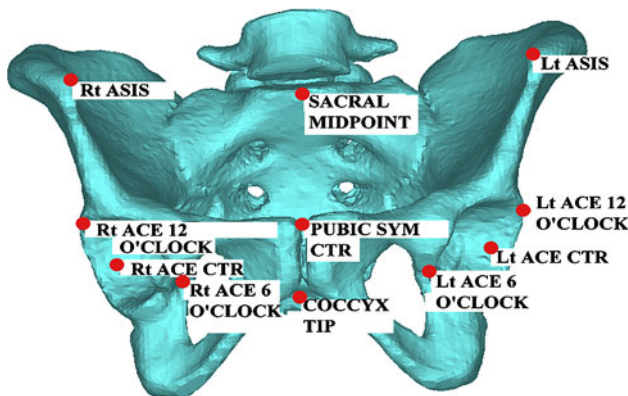
## Materials and Methods

We identified the pelvic CT scans of 50 randomly selected patients (100 acetabula) from a large database at our institution containing scans performed either for trauma or abdominal evaluation. All scans had been reviewed previously by a musculoskeletal radiologist for the original concerns. Scans with fractures, bone or soft tissue tumors, hardware, open growth plates, osteopenia, OA, or evidence of prior surgery were excluded from the study. All scans included the top of the sacrum down to the level of the lesser trochanters. The section thickness was 2.5 mm or thinner in all cases. There were 25 males and 25 females with an average age of  $39 \pm 12$  years (range, 16–62 years). This study was performed in full compliance with the University of California at Davis Institutional Review Board.

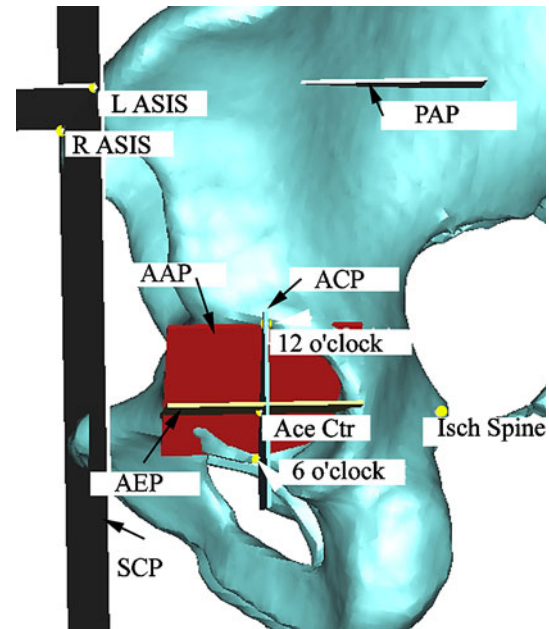
The scans were entered in a commercially available software package (Mimics; Materialise, Ann Arbor, MI, USA), and 3-D surface models were created. The femora were removed from the 3-D models to facilitate detailed analysis of the acetabula. A specialized acetabular analysis module was created in the software. In each case, the following points were selected manually: bilateral anterior superior iliac spines (ASIS), ischial spines, the sacral midpoint (defined as the anterior midpoint of the superior endplate of S1), pubic symphysis center, and coccyx (defined as the anterior midpoint of C1) (Fig. 1).

Two specialized measurement spheres were created in a commercially available computer-assisted design software program (Solidedge; UGS, Plano, TX, USA) containing seven evenly spaced parallel planes running through each sphere with the fourth plane bisecting the sphere. A series of anatomic planes were constructed for each pelvis (Fig. 2). A summary of the definitions of each plane is provided (Table 1). The standard coronal plane (SCP) was defined as the plane formed between both ASIS points and the pubic symphysis. This plane is approximately vertical with upright standing [2, 4, 6, 20] but can vary from  $10.4^\circ \pm 7.4^\circ$  forward rotation in the supine position to  $5.0^\circ \pm 9.4^\circ$  forward rotation in the standing position [2]. The pelvic axial plane (PAP) was defined as the plane

passing through both ASIS points and positioned normal to the SCP. This plane is approximately horizontal with upright standing. The sagittal plane (SP) was defined as the



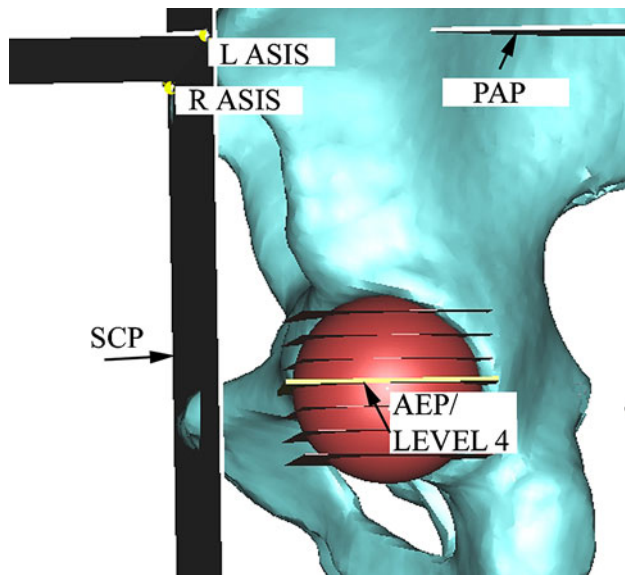
**Fig. 1** Anatomic points are placed on the 3-D virtual model of the pelvis. Rt ASIS = right anterior superior iliac spine; Rt ACE Ctr = right acetabular center; Rt ACE 12 o'clock = right acetabulum 12 o'clock position; Rt ACE 6 o'clock = right acetabulum 6 o'clock position; Lt ASIS = left anterior superior iliac spine; Lt ACE Ctr = left acetabular center; Lt ACE 12 o'clock = left acetabulum 12 o'clock position; Lt ACE 6 o'clock = left acetabulum 6 o'clock position; Pubic Sym Ctr = pubic symphysis center.



**Fig. 2** The standard coronal plane (SCP) includes both anterior superior iliac spine (ASIS) points and the pubic symphysis. The pelvic axial plane (PAP) runs through both ASIS points and is normal to the SCP. Planes used in the analysis of the acetabular abduction include the acetabular equatorial plane (AEP), which is parallel to the PAP and is shown in yellow (black arrow), and the acetabular coronal plane (ACP), which is parallel to the SCP and is shown in blue (black arrow). The ACP and the AEP run through the center of the acetabulum. The acetabular abduction plane (AAP) is shown in red (black arrow) and runs through the 6 o'clock and 12 o'clock positions (white arrowheads) and is normal to the SCP. Acetabular abduction is calculated as the angle between the AAP and the AEP. L = left; R = right.

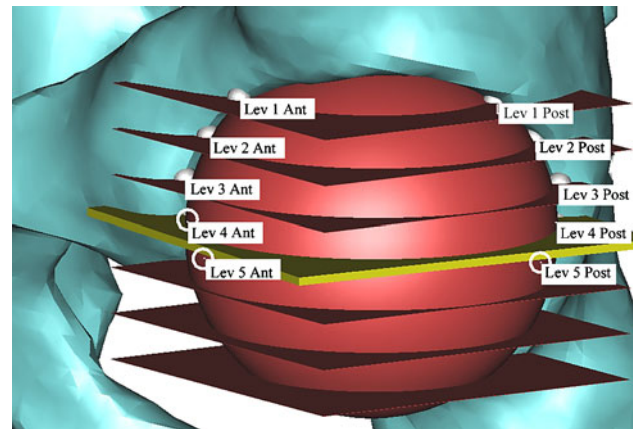
**Table 1.** Anatomic planes and their descriptions

Plane	Description
Standard coronal plane (SCP)	Intersects bilateral anterior superior iliac spines (ASIS) and pubic symphysis
Pelvic axial plane (PAP)	Intersects bilateral ASIS and is normal to the SCP
Sagittal plane (SP)	Intersects the midpoint of anterior S1 body and the pubic symphysis center and is normal to the SCP and PAP
Acetabular equatorial plane (AEP)	Intersects acetabular center, is parallel to the PAP, is perpendicular to the SCP
Acetabular coronal plane (ACP)	Intersects the acetabular center and is parallel to the SCP; the intersections of the plane and the superior and inferior rim of the acetabulum define the 6 o'clock and 12 o'clock points
Acetabular abduction plane (AAP)	Intersects the superior and inferior acetabular points (6 o'clock and 12 o'clock points) and is normal to the SCP
Level 1 acetabular version plane (Level 1 AVP)	Intersects Level 1 anterior and posterior points and is perpendicular to the PAP and AEP
Level 2 acetabular version plane (Level 2 AVP)	Intersects Level 2 anterior and posterior points and perpendicular to the PAP and AEP
Level 3 acetabular version plane (Level 3 AVP)	Intersects Level 3 anterior and posterior points and perpendicular to the PAP and AEP
Level 4 acetabular version plane (Level 4 AVP)	Intersects Level 4 anterior and posterior points and perpendicular to the PAP and AEP
Level 5 acetabular version plane (Level 5 AVP)	Intersects Level 5 anterior and posterior points and perpendicular to the PAP and AEP

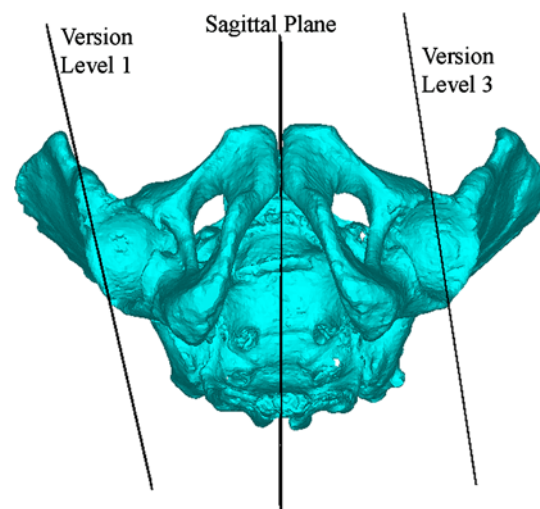


**Fig. 3** Anatomic planes of reference for the pelvis and acetabulum include the pelvic axial plane (PAP), the standard coronal plane (SCP), and the acetabular equatorial plane (AEP). After establishment of the AEP, the seven-level sphere (shown in red) is reoriented around its center such that its midlevel (Level 4) corresponds to the AEP. L = left; R = right; ASIS = anterior superior iliac spine.

plane that passes through the sacral midpoint, runs through the center of the pubic symphysis, and is normal to the SCP and the PAP. The measurement spheres were sized and positioned manually to best outline the acetabular anatomy on all cuts. The measurement spheres then were rotated around their center and the center of the acetabulum such that their seven planes were exactly parallel to the PAP (Fig. 3). In this way, the equatorial acetabulum corresponded to Level 4 of the measurement sphere and defined the acetabular equatorial plane (AEP), which was defined as the plane that passes through the center of the acetabulum and is parallel to the PAP. The acetabular coronal plane (ACP) was defined as the plane passing through the acetabular center and parallel to the SCP. The point on the acetabulum where the ACP intersected the rim superiorly was labeled the 12 o'clock point and represented the most superior aspect of the acetabulum (Fig. 2). The point where the ACP intersected the acetabular rim inferiorly was labeled the 6 o'clock point and represented the inferior-most aspect of the acetabulum (Fig. 2). The acetabular abduction plane (AAP) was defined as the plane passing through the 12 and 6 o'clock points and normal to the SCP. To determine AV at multiple levels, points were plotted manually in the software where each of the seven parallel planes on the measurement sphere intersected the anterior and posterior rim of the acetabulum (Fig. 4). AV planes (AVPs) were created and defined as the plane formed between the anterior and posterior points at each level and normal to the PAP (Fig. 5). These were created at Levels 1



**Fig. 4** A seven-layer sphere is overlaid on the left acetabulum, with Level 4 aligned with the acetabular equatorial plane (AEP) (shown in yellow). The intersection of each of the spheres with the rim of the acetabulum defines that level's anterior and posterior version points. In this case, Level 4 Anterior, Level 5 Anterior, and Level 5 Posterior are hidden around the back of the seven-layer sphere (points shown as white open circles). Lev = level; Ant = anterior; Post = posterior.



**Fig. 5** An inferior view of the pelvis shows the version planes of the acetabulum. Version has a positive value (anteversion) if the AVP and SP would intersect anteriorly relative to the pelvis. Version has a negative value (retroversion) if the planes would intersect posteriorly. In this example, the "Version Level 1" refers to the Level 1 version of the right hip that intersects the SP posteriorly and thus is retroverted. In contrast, "Version Level 3" refers to the Level 3 version of the left hip that intersects the SP anteriorly and thus is anteverted.

to 5. They were not created at Levels 6 and 7 owing to the lack of consistency of the intersection points on the anatomy of the inferior acetabulum. The AV at each level tested was calculated as the angle between the AVP and the SP as these two planes varied from one another in only one degree of freedom, namely the degree of AV. Version was given a positive value (anteversion) or a negative value

(retroversion) based on the relationship between each AV and the SP (Fig. 5). Once all points had been placed, acetabular abduction was measured automatically by the software as the angle between the AAP and the AEP. The interASIS distance, interacetabular distance, and interischial spinous distances also were measured in the same manner. Interobserver and intraobserver reliability analyses were performed using intraclass correlation coefficients (ICCs) for the analysis method and were performed by two observers at two times, a minimum of 2 weeks apart for each observer on three specimens (six hips). The ICCs for the two sessions were 0.997 and 0.994 for the first (AAJ) and second observer (AP), respectively (intraobserver reliability). The ICC between the two observers was 0.996 and 0.997 for the first and second sessions, respectively (interobserver reliability).

The prevalence of acetabular retroversion at each level and overall was determined. To assess for a torsional abnormality of the pelvis at the level of the acetabulum, the distance from the ischial spine tip to the sagittal plane was divided by the acetabular center to the sagittal plane distance to calculate an ischial spine index (ISI) for each hip, thus standardizing the ischial spine position to the size of the pelvis.

To determine whether acetabular retroversion represented a torsional phenomenon of the entire pelvic segment containing the acetabulum and the ischial spine, simple linear regression was used. This analysis was first performed to determine the relationship between version at Levels 1, 2, 3, and 5 and version at the midacetabular level, Level 4. Subsequently, the same regression method was used to evaluate the relationship between ISI, as a marker of ischial spine distance from the sagittal plane, and version at Level 4. The coefficient of determination,  $r^2$ , and the sample correlation coefficient,  $r$ , were obtained.

Differences in each measurement were compared based on gender using ANOVA. Post hoc testing was performed with the Bonferroni-Dunn method. Linear regression was performed using Excel® (Microsoft Corp, Redmond, WA, USA). ICC and ANOVA were performed with SPSS® (Version 9; SPSS Inc, Chicago, IL, USA) and StatView® software (SAS Institute Inc, Cary, NC, USA), respectively.

## Results

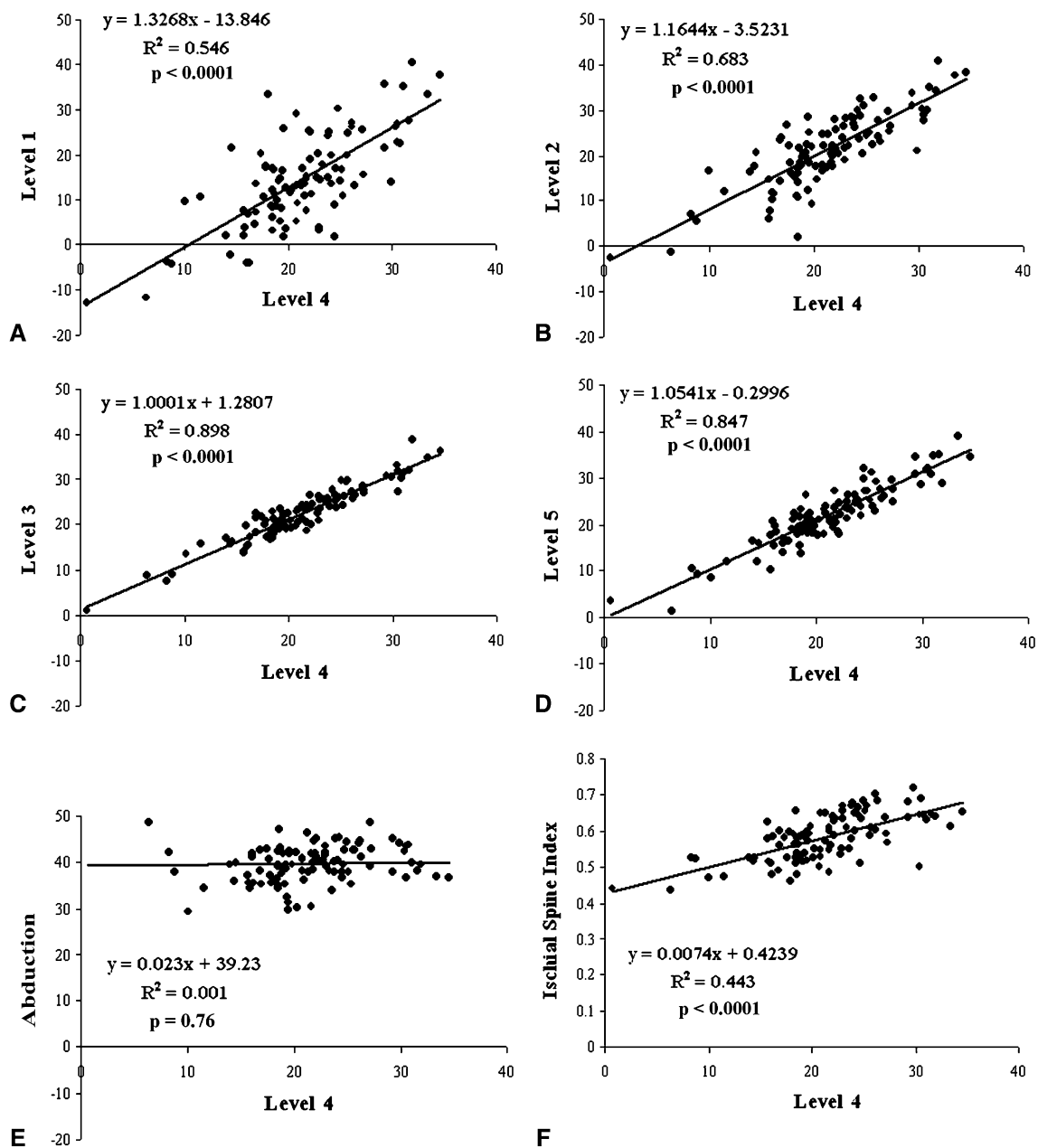
The mean ( $\pm$  SD) anteversion at the midlevel of the acetabulum was  $21.3^\circ \pm 5.8^\circ$ . The anteversion decreased and was more variable at the superior levels of the acetabulum. In the uppermost level of the acetabulum, anteversion was  $14.4^\circ \pm 10.5^\circ$ . Acetabular abduction was  $39.7^\circ \pm 4.3^\circ$ . The ISI measured  $0.6 \pm 0.1$  (Table 2).

The prevalence of acetabular retroversion overall was 7% (seven of 100 acetabula, in two pelvis bilaterally, in three unilaterally). Of the seven retroverted acetabula, five occurred in males (one bilaterally, three unilaterally) and bilateral retroversion occurred in one female. The prevalence of retroversion was 7% (seven of 100 acetabula, two bilaterally, three unilaterally) at Level 1 and 2% (two of 100 acetabula, one pelvis bilaterally) at Level 2. At each level from 1 to 5, females had higher anteversion values than males (Table 2). Retroversion did not occur in this series of pelvis at Levels 3, 4, or 5. Two acetabula in two separate male pelvis did not have a Level 1 AV measurement because of excessive acetabular coverage caused by an abnormally deep acetabulum. We observed correlations between Level 1 and Level 4 AV ( $r = 0.74$ ), the ISI and Level 4 AV ( $r = 0.67$ ), Level 2 and Level 4 AV ( $r = 0.83$ ), Level 3 and Level 4 AV ( $r = 0.95$ ), and Level 4 and Level 5 AV ( $r = 0.92$ ) (Fig. 6).

**Table 2.** Quantitative results of pelvimetry, acetabular abduction/inclination, and acetabular version at five levels

Parameter	Males	Females	Total	p Value
Acetabular cup diameter (mm)	51.1 $\pm$ 2.5 (47.1–56.4)	45.4 $\pm$ 2.0 (43.1–49.9)	48.2 $\pm$ 3.7 (43.1–56.4)	< 0.0001
Interanterior superior iliac spine distance (mm)	228.0 $\pm$ 14.7 (205.5–258.2)	222.4 $\pm$ 18.6 (180.5–156.7)	225.2 $\pm$ 16.9 (180.5–258.2)	0.3656
Interacetabular distance (mm)	169.3 $\pm$ 7.8 (154.0–183.0)	169.9 $\pm$ 10.0 (150.7–187.1)	169.6 $\pm$ 8.9 (150.7–187.1)	0.7502
Interischial spinous distance (mm)	90.2 $\pm$ 8.0 (74.8–109.2)	107.2 $\pm$ 6.7 (94.5–121.1)	98.7 $\pm$ 11.3 (74.8–121.1)	< 0.0001
Ischial spine index	0.5 $\pm$ 0.04 (0.4–0.6)	0.6 $\pm$ 0.04 (0.5–0.7)	0.6 $\pm$ 0.1 (0.4–0.7)	< 0.0001
Acetabular abduction/inclination (°)	39.4 $\pm$ 5.4 (29.4–57.0)	40.0 $\pm$ 2.9 (35.1–45.4)	39.7 $\pm$ 4.3 (29.4–57.0)	0.6904
Level 1 version (°)	11.6 $\pm$ 9.4 (–12.9–29.1)	17.0 $\pm$ 10.9 (–4.34–40.5)	14.4 $\pm$ 10.5 (–12.9–40.5)	0.0488
Level 2 version (°)	18.2 $\pm$ 7.4 (–2.4–28.57)	24.3 $\pm$ 7.8 (5.5–40.9)	21.2 $\pm$ 8.1 (–2.4–40.9)	0.0018
Level 3 version (°)	20.0 $\pm$ 4.8 (1.1–27.5)	25.1 $\pm$ 6.2 (7.5–38.8)	22.5 $\pm$ 6.1 (1.1–38.8)	0.002
Level 4 version (°)	18.9 $\pm$ 5.0 (0.7–30.47)	23.6 $\pm$ 5.5 (8.3–34.6)	21.3 $\pm$ 5.8 (0.7–34.6)	0.0014
Level 5 version (°)	19.7 $\pm$ 5.6 (1.38–32.09)	24.5 $\pm$ 6.7 (9.2–39.1)	22.1 $\pm$ 6.6 (1.38–39.1)	0.0033

Values are presented as mean  $\pm$  SD, with range in parentheses.



**Fig. 6A–F** Simple linear regression plots are shown for (A) Level 1 versus Level 4 (midacetabular) AV, (B) Level 2 versus Level 4 AV, (C) Level 3 versus Level 4 AV, (D) Level 5 versus Level 4 AV, (E) abduction versus Level 4 AV, and (F) ISI versus Level 4 AV.

## Discussion

Numerous structural deformities of the acetabulum are associated with hip OA. Current methods of evaluating acetabular anatomy are prone to inaccuracy from patient positioning and pelvic tilt. We established a quantitative measurement method using 3-D models to measure AV, abduction, and ischial spine position using an ISI. Using this method, we determined its prevalence and whether

retroversion was isolated to the superior acetabulum or involved the entire acetabulum and/or the pelvic segment including the acetabulum and the ischial spine.

There are some limitations to this study. First, the sample size was small with 50 subjects (100 acetabula). Prior studies determining the prevalence of retroversion in the general population have evaluated similar numbers [7, 9]. However, all measurements and 3-D reconstructions were performed by one observer (AP) and confirmed by a

second observer (AAJ). Second, the technique is currently time consuming, limiting its clinical utility. It requires manual segmentation of the bone in the software, placement and positioning of the measurement spheres, and placement of a total of 42 points, thus requiring approximately 1 hour of technician time per case. Development of an automated method for these calculations in the future would facilitate the establishment of normal and pathologic values in a larger number of pelvic specimens. Third, clinical information for the patients was not available, leading to a potential selection bias. Every effort was made to select a random sample from a large database of pelvic CT scans, and none of the patients had any signs of trauma based on the assessment of a musculoskeletal radiologist. Fourth, plain radiographs of these hips were not available, making comparisons of our findings to those of standard radiographs impossible. This information would be helpful as standard radiographs are widely available and a correlation of retroversion using this technique to the radiographic appearance would be informative. Fifth, we present data regarding acetabular anatomy in the static position referencing the standard coronal plane. Some studies have shown this plane can be variable in vivo [2, 4, 20, 38]. Zilber et al. [38] addressed the relationship among caudal, cranial, and central anteversion with various degrees of pelvic tilt. They dissected 10 complete pelvic specimens and performed CT scans by positioning the specimens with 0°, 20°, 40°, and 60° of sacral gradient (sacral slope). Sacral gradient was defined as the angle between the upper endplate of S1 and the horizontal plane. The sacral gradient averages 60° in the supine position [38], 40° in standing [19], and between 0° and 29° in the sitting position [18]. These authors [38] found anteversion measurements in all three positions diminished with forward pelvic tilt. The anteversion values at the 40° and 60° sacral gradients were slightly higher and lower, respectively, than the values obtained for anteversion in other studies (Table 3). This could be a result of their small number of specimens and the variability of sacral gradient in vivo compared with the cadaveric study. Lembeck et al. [20] measured pelvic tilt in 30 asymptomatic individuals using an inclinometer. They assigned negative values to pelvis that were tilted posteriorly (extended). They found the average pelvic tilt was -8° (range, -17°-+3°) in the lying position (relative to the horizontal) and -12° (range, -27°-+3°) in the standing position (relative to the vertical). Using a correction for soft tissue thickness over each bony prominence, these authors estimated the pelvis was reclined (extended) between 8° in standing and 4° in the supine position. Dardenne et al. [4] also used ultrasound in assessing dynamic pelvic position. However, their ultrasound probes were directly attached to a surgical navigation system. They found 2.4° ± 5.1° of anterior tilt

(flexion) relative to the vertical plane in the standing position and 6.8° ± 3.5° of anterior tilt (flexion) relative to the horizontal plane in the supine position. The issues with the standard coronal plane were addressed intraoperatively by Babisch et al. [2]. They evaluated CT scans of 30 patients with OA of the hip with the patients in the supine position and lateral radiographs in the standing position. They noted an inclination (flexion) of the pelvis of 10.4° ± 7.4° and 5° ± 9.4° in the supine and standing positions, respectively. They developed normograms to allow surgical navigation systems to place the acetabular component in THA with consideration of the pelvic tilt. A summary of the literature on dynamic pelvic position suggests that the anterior pelvic plane is routinely positioned close to the horizontal plane in the supine position and close to the vertical plane in the standing position. In this study, we did not make specific adjustments for pelvic tilt. This decision was made based on our objective to clearly define the acetabular anatomy regardless of positional changes and to optimize reliability of the measurements. Additional studies would be needed to correlate pelvic-specific anatomic data using this technique to in vivo positional data.

Using this technique, midacetabular anteversion was 21.3° ± 5.8°. This value is consistent with previous measurements reported in the literature ranging from 15° to 20° [3, 11, 21, 22, 26–28, 32, 35, 36] (Table 3). We used the same software package to develop a standardized method to measure the distance from the ischial spine from the sagittal plane, termed the ISI.

We found a prevalence of acetabular retroversion of 7%, similar to published values of 5% to 6% [7, 9]. However, this prevalence was substantially lower than the 22% reported by Jamali et al. [13]. There are two potential explanations. First, in that series, the measurements were performed by hand on cadaveric specimens at a level 5 mm below the superior-most point of the acetabulum. In our study, a given distance was not used to determine the cranial acetabulum but rather a standardized measurement at a level 1/8 of the distance from the top of the acetabular cavity was used (at Level 1 of seven with Level 4 as the equator). Second, manual measurements performed in that series may have been less accurate than the computerized measurements performed here. A previous study showed the measurements performed in this software program are more accurate and precise than manual linear and angular measurements [12].

Our data are consistent with those of Giori and Trousdale [9], who suggested the radiographic findings seen in acetabular retroversion are not attributable solely to excessive bone anteriorly. However, in contrast to their suggestion that inadequate posterior coverage is solely to blame, our data would indicate that there is a torsional effect in acetabular retroversion that involves the pelvic

**Table 3.** Acetabular anteversion measurements reported in the literature

Study	Year	Number of cases	Method	Anteversion (combined)	Anteversion (males)	Anteversion (females)
Reikeras et al. [27]	1983	47 CTs for various disorders "other than hip joint disease" (21 males, 26 females)	2-D axial CT measurement	17 ± 6°	16 ± 5°	18° ± 6°
Hoiseth et al. [11]	1989	40 (23 males, 17 females)	2-D axial CT measurement	19.4°	18.4°	20.7°
Maruyama et al. [21]	2001	200 specimens from an anthropologic collection (100 males, 100 females)	Manual measurements	19.9° ± 6.6°	18.5° ± 5.8°	21.3° ± 7.1°
Jamali et al. [13]	2006	43 specimens from an anthropologic collection	Manual measurements	20.1° ± 6.4°	NA	NA
Stem et al. [32]	2006	100 patients undergoing CT scanning for "nonorthopaedic pathology" (42 males, 58 females)	2-D axial CT measurement	23° ± 5°	22° ± 6°	25° ± 5° (age > 70 years) 23° ± 5° (age < 70 years)
Reynolds et al. [28]	1999	87 patients with hip pain, "normal radiographs per author's evaluation"	2-D axial CT measurement	21° ± 20°	NA	NA
Murtha et al. [26]	2008	42 hips contralateral to THA	3-D CT-generated models	21.8° (calculated)	19.3° (8.5°–32.3°)	24.1° (14.0°–33.3°)
Bargar et al. [3]	2010	46 patients scheduled for THA (31 males, 15 females)	2-D axial CT measurement	15.1° ± 6.7°	NA	NA
Current study	2010	50 patients (25 males, 25 females)	3-D CT-generated models	21.3° ± 5.8°	18.9° ± 5.0°	23.6° ± 5.5°

Values are expressed as mean ± SD, with range in parentheses; 2-D = two-dimensional; 3-D = three-dimensional; NA = not available.



segment that encompasses the entire acetabulum and the ischial spine. Furthermore, Jamali et al. [13] found a linear relationship between cranial and central AV in a study of cadaveric pelvis measured manually, again indicating a torsional effect on AV. Finally, Kalberer et al. [15] studied 149 standardized AP pelvic radiographs and determined the presence of a visible ischial spine was highly associated with the cross-over sign and acetabular retroversion. A visible ischial spine indicates a smaller distance between the ischial spine and the sagittal plane and is a nonquantitative manifestation of the ISI we describe in this study. Our findings support theirs based on a positive linear correlation between the ISI and the central acetabular anteversion. As the ischial spine distance from the sagittal plane increases so does the degree of acetabular anteversion.

We found acetabular anatomy can be measured reproducibly using 3-D CT-generated models regardless of patient positioning in the scanner. We observed a correlation between cranial and central acetabular anteversion and between the ISI and central anteversion, suggesting acetabular retroversion is a phenomenon involving the entire pelvic segment containing the acetabulum and the ischial spine. Future effort will be directed toward automating the technique and potentially incorporating in vivo data on pelvic tilt to consider functional acetabular anteversion.

This information may be of benefit to surgeons in reproducing normal acetabular position and alignment at the time of periacetabular osteotomy or acetabular recontouring procedures. The recognition of a localized abnormal retroversion in the superior acetabulum would suggest optimal treatment with a superior anterior acetabuloplasty. In contrast if the acetabulum is abnormally retroverted at all levels, a more logical approach would be to consider reorientation of the entire socket using a periacetabular osteotomy. The nuances and degrees of such deformities and their symptomatic correlates are currently unknown and would benefit from further investigation.

**Acknowledgment** We thank Mazie Ngai for assistance with preparation of this manuscript.

**Open Access** This article is distributed under the terms of the Creative Commons Attribution Noncommercial License which permits any noncommercial use, distribution, and reproduction in any medium, provided the original author(s) and source are credited.

## References

- Anda S, Svenningsen S, Grontvedt T, Benum P. Pelvic inclination and spatial orientation of the acetabulum: a radiographic, computed tomographic and clinical investigation. *Acta Radiol.* 1990;31:389–394.
- Babisch JW, Layher F, Amiot LP. The rationale for tilt-adjusted acetabular cup navigation. *J Bone Joint Surg Am.* 2008;90:357–365.
- Bargar WL, Jamali AA, Nejad AH. Femoral anteversion in THA and its lack of correlation with native acetabular anteversion. *Clin Orthop Relat Res.* 2010;468:527–532.
- Dardenne G, Dusseau S, Hamitouche C, Lefevre C, Stindel E. Toward a dynamic approach of THA planning based on ultrasound. *Clin Orthop Relat Res.* 2009;467:901–908.
- Ecker TM, Tannast M, Puls M, Siebenrock KA, Murphy SB. Pathomorphologic alterations predict presence or absence of hip osteoarthritis. *Clin Orthop Relat Res.* 2007;465:46–52.
- Eckman K, Hafez MA, Ed F, Jaramaz B, Levison TJ, Digioia AM 3rd. Accuracy of pelvic flexion measurements from lateral radiographs. *Clin Orthop Relat Res.* 2006;451:154–160.
- Ezoe M, Naito M, Inoue T. The prevalence of acetabular retroversion among various disorders of the hip. *J Bone Joint Surg Am.* 2006;88:372–379.
- Ganz R, Parvizi J, Beck M, Leunig M, Notzli H, Siebenrock KA. Femoroacetabular impingement: a cause for osteoarthritis of the hip. *Clin Orthop Relat Res.* 2003;417:112–120.
- Giori NJ, Trousdale RT. Acetabular retroversion is associated with osteoarthritis of the hip. *Clin Orthop Relat Res.* 2003;417:263–269.
- Harris WH. Etiology of osteoarthritis of the hip. *Clin Orthop Relat Res.* 1986;213:20–33.
- Hoiseith A, Reikeras O, Fonstelién E. Lack of correlation between femoral neck anteversion and acetabular orientation: radiography and computed tomography in cadavers and in vivo. *Acta Orthop Scand.* 1989;60:93–96.
- Jamali AA, Deuel C, Perreira A, Salgado CJ, Hunter JC, Strong EB. Linear and angular measurements of computer-generated models: are they accurate, valid, and reliable? *Comput Aided Surg.* 2007;12:278–285.
- Jamali AA, Mladenov K, Meyer DC, Martinez A, Beck M, Ganz R, Leunig M. Anteroposterior pelvic radiographs to assess acetabular retroversion: high validity of the “cross-over-sign”. *J Orthop Res.* 2007;25:758–765.
- Jaramaz B, DiGioia AM 3rd, Blackwell M, Nikou C. Computer assisted measurement of cup placement in total hip replacement. *Clin Orthop Relat Res.* 1998;354:70–81.
- Kalberer F, Sierra RJ, Madan SS, Ganz R, Leunig M. Ischial spine projection into the pelvis: a new sign for acetabular retroversion. *Clin Orthop Relat Res.* 2008;466:677–683.
- Kubiak-Langer M, Tannast M, Murphy SB, Siebenrock KA, Langlotz F. Range of motion in anterior femoroacetabular impingement. *Clin Orthop Relat Res.* 2007;458:117–124.
- Lavigne M, Parvizi J, Beck M, Siebenrock KA, Ganz R, Leunig M. Anterior femoroacetabular impingement: part I. Techniques of joint preserving surgery. *Clin Orthop Relat Res.* 2004;418:61–66.
- Lazennec JY, Charlot N, Gorin M, Roger B, Arafati N, Bissery A, Saillant G. Hip-spine relationship: a radio-anatomical study for optimization in acetabular cup positioning. *Surg Radiol Anat.* 2004;26:136–144.
- Legaye J, Duval-Beaupere G, Hecquet J, Marty C. Pelvic incidence: a fundamental pelvic parameter for three-dimensional regulation of spinal sagittal curves. *Eur Spine J.* 1998;7:99–103.
- Lembeck B, Mueller O, Reize P, Wuelker N. Pelvic tilt makes acetabular cup navigation inaccurate. *Acta Orthop.* 2005;76:517–523.
- Maruyama M, Feinberg JR, Capello WN, D’Antonio JA. The Frank Stinchfield Award: Morphologic features of the acetabulum and femur: anteversion angle and implant positioning. *Clin Orthop Relat Res.* 2001;393:52–65.
- McKibbin B. Anatomical factors in the stability of the hip joint in the newborn. *J Bone Joint Surg Br.* 1970;52:148–159.
- Murphy S, Tannast M, Kim YJ, Buly R, Millis MB. Debridement of the adult hip for femoroacetabular impingement: indications

- and preliminary clinical results. *Clin Orthop Relat Res.* 2004;429:178–181.
24. Murray DW. The definition and measurement of acetabular orientation. *J Bone Joint Surg Br.* 1993;75:228–232.
  25. Murray RO. The aetiology of primary osteoarthritis of the hip. *Br J Radiol.* 1965;38:810–824.
  26. Murtha PE, Hafez MA, Jaramaz B, DiGioia AM III. Variations in acetabular anatomy with reference to total hip replacement. *J Bone Joint Surg Br.* 2008;90:308–313.
  27. Reikeras O, Bjerkreim I, Kolbenstvedt A. Anteversion of the acetabulum and femoral neck in normals and in patients with osteoarthritis of the hip. *Acta Orthop Scand.* 1983;54:18–23.
  28. Reynolds D, Lucas J, Klaue K. Retroversion of the acetabulum: a cause of hip pain. *J Bone Joint Surg Br.* 1999;81:281–288.
  29. Siebenrock KA, Kalbermatten DF, Ganz R. Effect of pelvic tilt on acetabular retroversion: a study of pelvis from cadavers. *Clin Orthop Relat Res.* 2003;407:241–248.
  30. Siebenrock KA, Schoeniger R, Ganz R. Anterior femoro-acetabular impingement due to acetabular retroversion: treatment with periacetabular osteotomy. *J Bone Joint Surg Am.* 2003;85:278–286.
  31. Solomon L. Patterns of osteoarthritis of the hip. *J Bone Joint Surg Br.* 1976;58:176–183.
  32. Stem ES, O'Connor MI, Kransdorf MJ, Crook J. Computed tomography analysis of acetabular anteversion and abduction. *Skeletal Radiol.* 2006;35:385–389.
  33. Stulberg S, Cordell L, Harris W, Ramsey P, MacEwen G. Unrecognized childhood hip disease: a major cause of idiopathic osteoarthritis of the hip. In: Amstutz H, ed. *The Hip, Proceedings of the Third Open Scientific Meeting of the Hip Society.* St Louis, MO: CV Mosby; 1975:212–228.
  34. Tannast M, Zheng G, Anderegg C, Burckhardt K, Langlotz F, Ganz R, Siebenrock KA. Tilt and rotation correction of acetabular version on pelvic radiographs. *Clin Orthop Relat Res.* 2005;438:182–190.
  35. Tonnis D, Heinecke A. Acetabular and femoral anteversion: relationship with osteoarthritis of the hip. *J Bone Joint Surg Am.* 1999;81:1747–1770.
  36. Visser JD, Jonkers A, Hillen B. Hip joint measurements with computerized tomography. *J Pediatr Orthop.* 1982;2:143–146.
  37. Yao L, Yao J, Gold RH. Measurement of acetabular version on the axiolateral radiograph. *Clin Orthop Relat Res.* 1995;316:106–111.
  38. Zilber S, Lazennec JY, Gorin M, Saillant G. Variations of caudal, central, and cranial acetabular anteversion according to the tilt of the pelvis. *Surg Radiol Anat.* 2004;26:462–465.