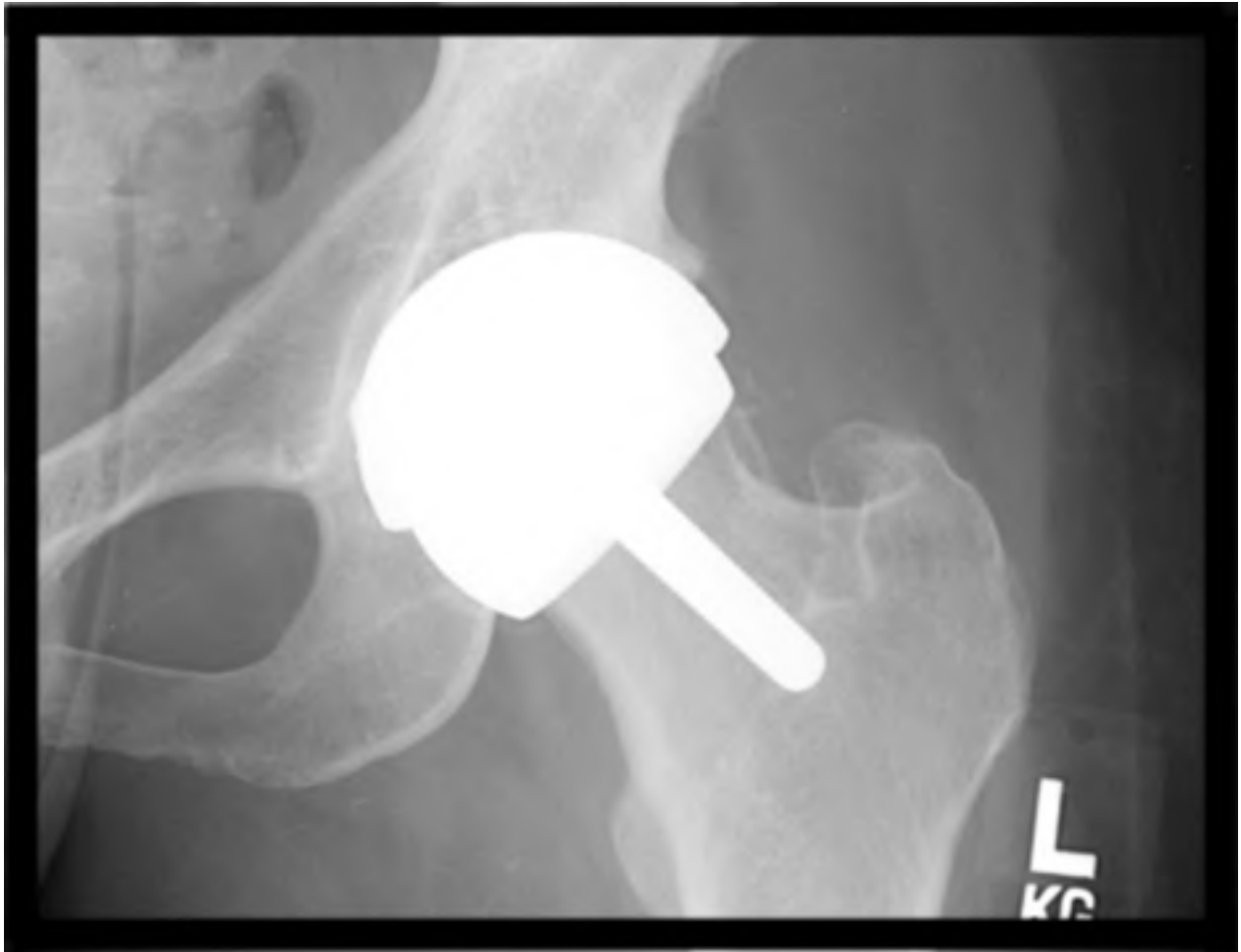


# Resurfacing Total Hip Arthroplasty: Rationale and Review

*Amir Jamali, MD, FACS  
Joint Preservation Institute  
San Francisco, California*



# Total Hip Resurfacing Arthroplasty

## Introduction

Total hip replacement is one of the most widely used and successful surgical procedures in the world today. This procedure has been performed for nearly 70 years but became largely successful based on the work of Sir John Charnley. Charnley, working in the UK, developed an implant and surgical procedure that allowed for low infection rate, low wear debris, and high clinical success. He advocated using polyethylene as a one piece cemented hemispherical cup on the hip socket and a metal femoral component stem, cemented into the femoral shaft. Since volumetric wear of the material was an issue, he was able to minimize this using a small femoral head diameter, approximately 22mm in size. There were, however, ongoing issues including the generation of wear which would ultimately lead to particulate debris being pumped throughout the joint and down the femoral shaft expanding what has been termed the effective joint space<sup>1</sup>. This debris was later found to cause a profound inflammatory response and activation of macrophages and osteoclasts, leading to an entity called osteolysis. The methyl-methacrylate cement would also not always hold up under these circumstances, leading to occasional early revision procedures, particularly in younger, more active, and larger patients. Over the past 30 years, a number of strategies have been employed to reduce the rate of complications in standard hip replacement. These

replacements have been used since the time of Charnley's work including the widely used McKee-Farrar prosthesis<sup>2</sup>. These have done relatively well and occasionally have remained revision-free for long periods of time. In other instances, they have failed quickly with a profound metal reaction in the joint. It was later determined that the clearances between the metal components determined the fluid film lubrication and the function of these types of prostheses. Metal on metal hip replacements have enjoyed resurgence over the past 15 years in the United States. Other strategies to decrease wear included the use of ceramic on ceramic total hip replacements<sup>3</sup>. These had been used in Europe for over 20 years but were occasionally associated with catastrophic failure due to fracture of the components or profound osteolysis from the highly reactive ceramic wear debris. Both of these risks have been reduced substantially using improved material science; however, fractures of the ceramic head are still reported<sup>4,5</sup>. Additionally, with the newer implants, a rate of squeaking of up to 10% has been reported<sup>6</sup>. The most successful improvement in the bearing surfaces of total hip replacements has been the cross-linking of polyethylene<sup>7</sup>. This can be performed either with electron beam or gamma irradiation<sup>8,9</sup>. This has been shown to decrease wear substantially both in simulator studies as well as in vivo.

Resurfacing total hip replacement has been performed in the United States as an FDA approved procedure since 2006. Resurfacing total hip replacements differ from standard hip replacements in that they do not remove the femoral head bone and instead place a cap on the head after reshaping it using specialized reamers. The obvious advantage is that more bone is preserved on the head and that the femoral canal is not opened up to the particulate debris from the joint. In its early stages, resurfacings were performed with a metal head and

a polyethylene one piece cup. By necessity, these heads and cups had to have a large diameter to accommodate the native femoral head. Such large diameter cups, made prior to the cross-linking of polyethylene, have been shown to have higher volumetric wear. Not surprisingly, these early resurfacing total hip replacements did not enjoy a high degree of clinical success<sup>10,11</sup>. The use of metal on metal hip resurfacings opened up new possibilities due to their low wear characteristics. Ironically, it has been shown that large metal heads have lower wear<sup>12</sup>. This would allow for a lower dislocation rate. In the modern era, MOM resurfacing THA has enjoyed a high degree of success in the hands of the pioneers of the field<sup>13-16</sup>.

Most studies performed in the United States have consisted either of implant designers with the potential for biased reporting or in series with multiple surgeons with little pre-existing training with resurfacing THA. Much of the surgical literature demonstrates a much lower complication rate in the hands of high volume surgeons. However, most surgeries are performed in the hands of low volume surgeons based on demographic factors. Thus, to truly assess the public health impact of any procedure in the hands of the “average” surgeon, the optimal data is obtained from national registries. These registries provide limited data but do have information on implants used as well as revision rates. Fortunately, Australia has a relatively large national hip registry with a publicly available annual report<sup>17</sup>. The benefits of national registries are based on their large patient size. The tradeoff is limited data on patient function and performance. When the FDA approved implant with the widest use in both Australia and the United States, the Birmingham Hip Resurfacing (BHR, Smith

& Nephew, Memphis, TN) is compared to all standard hip replacements in the Australian registry, the revision rate is nearly equivalent. The BHR revision rate was 0.8 per 100 Observed Years compared to 0.9 per 100 Observed Years for the standard THAs in the registry (Table 1).

<b>Implants</b>	<b>N Revised</b>	<b>N Total</b>	<b>Obs. Years</b>	<b>Revisions Per 100 Obs. Yrs.</b>	<b>Exact 95% CI</b>
BHR	269	8427	34340	0.8	(0.69, 0.88)
All Standard THA	2366	80540	264203	0.9	(0.86, 0.93)

Table 1. Comparison of revisions of all standard THAs and the BHR hip resurfacing in the Australian Hip Registry, 2009 report.

Randomized, double-blinded prospective clinical trials (RCTs) are widely accepted as the gold standard in assessing device and drug safety and efficacy. However, their role is limited in the free market environment for elective surgery. This problem is largely responsible for the lack of such studies in evaluating orthopaedic devices used in joint arthroplasty. In the United States, patients would typically refuse any such study where they may be randomized to one treatment or another based on a computer generated randomization protocol. This is particularly true for a procedure billed as preferable for the young, active population. Fortunately, in Canada, a number of RCTs have been performed. The group from Montreal

has shown that resurfacing THA does not lead to higher bone loss on the acetabulum<sup>18</sup> and in another trial have shown that the functional results based on walking speed were equivalent between standard and resurfacing THAs<sup>19</sup>. However, this study was probably underpowered to assess other parameters such as UCLA activity<sup>20</sup> scores with only 24 patients per group. In a RCT from Vancouver<sup>21</sup>, 104 hips were randomized to resurfacing THA or standard metal on metal (MOM) THA. The functional results were equivalent but were notable for much higher metal ion levels in the standard MOM THA group. Both of these studies were performed with a non-FDA approved implant, the Zimmer Durom (Zimmer, Warsaw, IN, USA). Although there have been problems with the acetabular component fixation with this implant, the results do not appear to have any relation to these trials since in both the study by Lavigne<sup>19</sup> and the study by Garbuz<sup>21</sup> the identical cup was used for both the standard and resurfacing groups. Summarizing these two studies as well as my own clinical experience, resurfacing total hip replacement does not provide a significant advantage in performance compared to a large diameter standard total hip replacement.

In evaluating the entire spectrum of literature on total hip resurfacing, a few potential advantages can be noted. The first, and most important of these, is the potential for bone preservation on the femur. The effective joint space<sup>1</sup> can be viewed as all fluid spaces that communicate with the joint. This space is increased substantially with placement of a standard femoral stem. The opening of the femoral canal with the entry of joint wear debris predisposes to loosening of the femoral component as well as possible periprosthetic fractures. A second potential advantage with resurfacing is the protection of the femoral shaft from

trauma. Should a patient previously treated with an arthroplasty sustain a motor vehicle accident with severe trauma to the femur, it is not clear if the types and severity of the fractures would be different with a resurfacing or with a standard femoral prosthesis in place. Based on previous experience, with a standard hip prosthesis (Figures 1,2), there is a high likelihood of a catastrophic fracture of the femur with multiple fragments. The fixation of these fractures require extensive incisions, blood loss, higher complication rates, long hospital stays, loss of muscle function, and potentially higher rates of mortality.

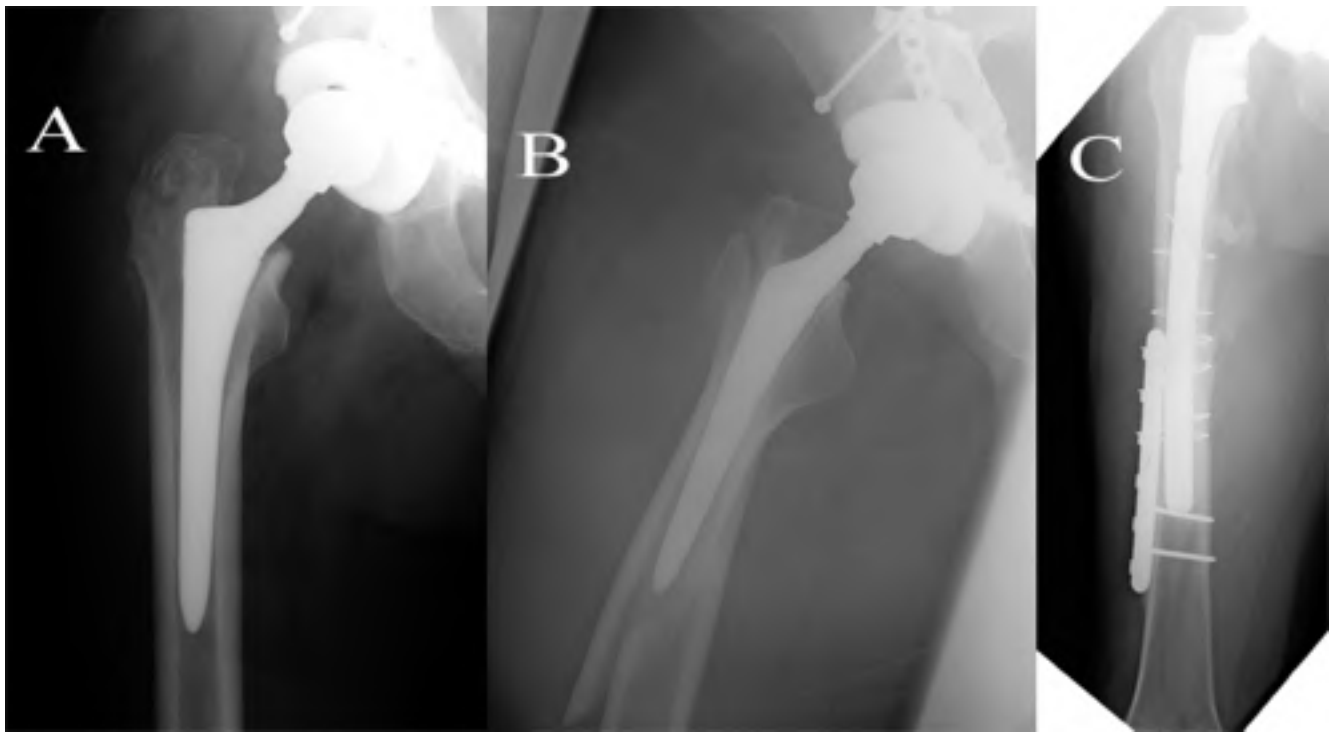
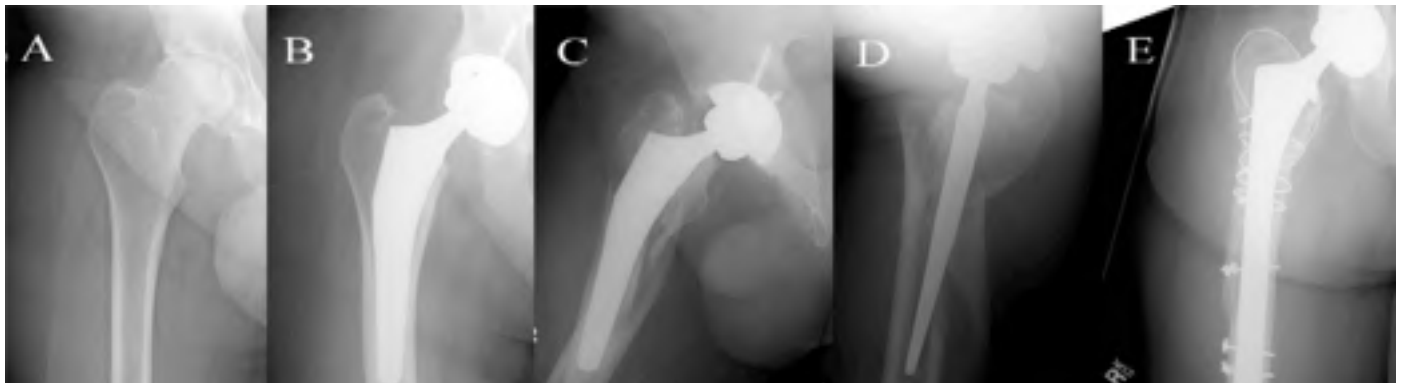


Figure 1. 60 year old male with post traumatic hip arthritis, treated with total hip replacement (A). He sustained a fall approximately one year after the index surgery with a severe periprosthetic fracture (B). This required revision fixation with a long stem prosthesis extending down the femoral shaft (C).

From a theoretical point of view, one would expect that if a femoral resurfacing were in place the fracture would be more likely to result in a femoral neck fracture or a simple femoral shaft fracture that could be treated with an intramedullary device in a minimally invasive manner. This would lead to bone preservation for the future, decreased hospital costs, as well as decreased morbidity and mortality.

Figure 2. 45 year old male with avascular necrosis (A) treated with uncemented total hip replacement (B). He had a bookshelf fall on him at 2 years post surgery and sustained a comminuted femoral periprosthetic fracture (C,D). He was treated with a long stem femoral prosthesis extending down the femoral shaft (E).

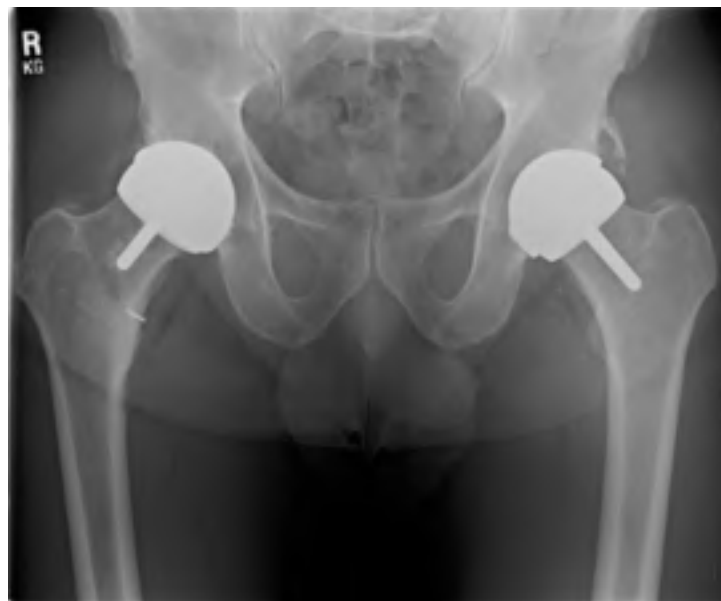

The final advantage of resurfacing total hip replacement over standard hip replacement is the more normal loading of the proximal femur with routine activities. This has been shown in a study using DEXA scanning by Kishida et al<sup>22</sup>. They compared bone den



sity between resurfacing and standard hip replacements. They found a significantly higher loss of bone stock in the proximal femur after standard THA compared to after resurfacing THA. In a study from our laboratory, femoral cadaveric specimens were covered with strain gauges<sup>23</sup>. The femurs were then loaded axially and proximal femoral strains were measured. This was performed sequentially with the native femur, followed by application of a resurfacing implant, followed by application of a cementless standard total hip replacement femoral component. Our results indicated essentially normal proximal femoral loading with resurfacing and substantially lower strains in the proximal femur with a standard hip replacement. This decrease in normal strains would be a predisposing factor for stress shielding and subsequent bone density loss in the proximal femur<sup>24</sup>.

Figure 3. A 60 year of male 4 years post resurfacing on the right side and 3 years post resurfacing on the left side. He currently enjoys water skiing and snow skiing 21 days in the past season.



In summary, much research still needs to be done on the topic of resurfacing total hip replacement. This would include biomechanical studies on the effect of trauma in the setting of femora with standard and resurfacing THA implants, larger randomized clinical studies, and more mature data from national registries.

## References

1. Schmalzried TP, Jasty M, Harris WH. Periprosthetic bone loss in total hip arthroplasty. Polyethylene wear debris and the concept of the effective joint space. *J Bone Joint Surg Am.* Jul 1992;74(6):849-863.
2. August AC, Aldam CH, Pynsent PB. The McKee-Farrar hip arthroplasty. A long-term study. *J Bone Joint Surg Br.* Aug 1986;68(4):520-527.
3. Hannouche D, Hamadouche M, Nizard R, Bizot P, Meunier A, Sedel L. Ceramics in total hip replacement. *Clin Orthop Relat Res.* Jan 2005(430):62-71.
4. Rhoads DP, Baker KC, Israel R, Greene PW. Fracture of an alumina femoral head used in ceramic-on-ceramic total hip arthroplasty. *J Arthroplasty.* Dec 2008;23(8):1239 e1225-1230.
5. Toran MM, Cuenca J, Martinez AA, Herrera A, Thomas JV. Fracture of a ceramic femoral head after ceramic-on-ceramic total hip arthroplasty. *J Arthroplasty.* Oct 2006;21(7):1072-1073.
6. Jarrett CA, Ranawat AS, Bruzzone M, Blum YC, Rodriguez JA, Ranawat CS. The squeaking hip: a phenomenon of ceramic-on-ceramic total hip arthroplasty. *J Bone Joint Surg Am.* Jun 2009;91(6):1344-1349.

7. Geerdink CH, Grimm B, Vencken W, Heyligers IC, Tonino AJ. Cross-linked compared with historical polyethylene in THA: an 8-year clinical study. *Clin Orthop Relat Res.* Apr 2009;467(4):979-984.
8. Muratoglu OK, Bragdon CR, O'Connor DO, Jasty M, Harris WH. A novel method of cross-linking ultra-high-molecular-weight polyethylene to improve wear, reduce oxidation, and retain mechanical properties. Recipient of the 1999 HAP Paul Award. *J Arthroplasty.* Feb 2001;16(2):149-160.
9. Oonishi H, Kadoya Y, Masuda S. Gamma-irradiated cross-linked polyethylene in total hip replacements--analysis of retrieved sockets after long-term implantation. *J Biomed Mater Res.* 2001;58(2):167-171.
10. de Waal Malefijt MC, Huiskes R. A clinical, radiological and biomechanical study of the TARA hip prosthesis. *Arch Orthop Trauma Surg.* 1993;112(5):220-225.
11. Head WC. Total articular resurfacing arthroplasty. Analysis of component failure in sixty-seven hips. *J Bone Joint Surg Am.* Jan 1984;66(1):28-34.
12. Smith SL, Dowson D, Goldsmith AA. The effect of femoral head diameter upon lubrication and wear of metal-on-metal total hip replacements. *Proc Inst Mech Eng H.* 2001;215(2):161-170.
13. Amstutz HC, Ball ST, Le Duff MJ, Dorey FJ. Resurfacing THA for patients younger than 50 year: results of 2- to 9-year followup. *Clin Orthop Relat Res.* Jul 2007;460:159-164.

14. Amstutz HC, Beaulé PE, Dorey FJ, Le Duff MJ, Campbell PA, Gruen TA. Metal-on-metal hybrid surface arthroplasty: two to six-year follow-up study. *J Bone Joint Surg Am.* Jan 2004;86-A(1):28-39.
15. Daniel J, Pynsent PB, McMinn DJ. Metal-on-metal resurfacing of the hip in patients under the age of 55 years with osteoarthritis. *J Bone Joint Surg Br.* Mar 2004;86(2):177-184.
16. McMinn DJ, Daniel J, Pynsent PB, Pradhan C. Mini-incision resurfacing arthroplasty of hip through the posterior approach. *Clin Orthop Relat Res.* Dec 2005;441:91-98.
17. *Hip and Knee Arthroplasty, Annual Report:* National Joint Replacement Registry, Australian Orthopaedic Association;2009.
18. Vendittoli PA, Lavigne M, Girard J, Roy AG. A randomised study comparing resection of acetabular bone at resurfacing and total hip replacement. *J Bone Joint Surg Br.* Aug 2006;88(8):997-1002.
19. Lavigne M, Therrien M, Nantel J, Roy A, Prince F, Vendittoli PA. The John Charnley Award: The functional outcome of hip resurfacing and large-head THA is the same: a randomized, double-blind study. *Clin Orthop Relat Res.* Feb;468(2):326-336.
20. Zahiri CA, Schmalzried TP, Szuszczewicz ES, Amstutz HC. Assessing activity in joint replacement patients. *J Arthroplasty.* Dec 1998;13(8):890-895.
21. Garbuz DS, Tanzer M, Greidanus NV, Masri BA, Duncan CP. The John Charnley Award: Metal-on-metal hip resurfacing versus large-diameter head metal-on-metal to

tal hip arthroplasty: a randomized clinical trial. *Clin Orthop Relat Res.* Feb;468(2):318-325.

22. Kishida Y, Sugano N, Nishii T, Miki H, Yamaguchi K, Yoshikawa H. Preservation of the bone mineral density of the femur after surface replacement of the hip. *J Bone Joint Surg Br.* Mar 2004;86(2):185-189.
23. Deuel CR, Jamali AA, Stover SM, Hazelwood SJ. Alterations in femoral strain following hip resurfacing and total hip replacement. *J Bone Joint Surg Br.* Jan 2009;91(1):124-130.
24. Bugbee WD, Culpepper WJ, 2nd, Engh CA, Jr., Engh CA, Sr. Long-term clinical consequences of stress-shielding after total hip arthroplasty without cement. *J Bone Joint Surg Am.* Jul 1997;79(7):1007-1012.